

UDC 616.831-005.4-036.11

DOI: 10.22141/2224-0713.16.3.2020.203443

S.M. Vynychuk¹, M.M. Prokopiv², L.M. Trepet¹, O.Ye. Fartushna³¹Oleksandrivska Clinical Hospital, Kyiv, Ukraine²Bogomolets National Medical University, Kyiv, Ukraine³Ukrainian Military Medical Academy, Kyiv, Ukraine

Clinical syndromes of a thalamic stroke in the lower lateral vascular territory: a prospective hospital-based cohort study

Abstract. Background. The article covers pathophysiological features and patterns of the occurrence of neurological, neuropsychological, and clinical vascular syndromes of thalamic strokes in the lower lateral vascular territory. The purpose of this study is to determine the features of clinical vascular syndromes of an acute thalamic stroke in the lower lateral vascular territory in a prospective hospital-based cohort study, providing a comprehensive clinical and neuroimaging analysis. **Materials and methods.** We have prospectively recruited 319 acute stroke patients, admitted within 24 hours from the onset of the stroke symptoms to the Neurological Center at an academic hospital (Oleksandrivska Clinical Hospital) in Kyiv, Ukraine. Comprehensive neurological, clinical, laboratory, ultrasound, and neuroimaging examinations were performed to all patients. **Results.** MRI/CT-proven thalamic stroke was diagnosed in 34 (10.6 %) of 319 patients, forming a study group. Twenty-two of 34 patients (average age 61.9 ± 10.2 years) were diagnosed with an acute isolated ischemic thalamic infarction, and 12 people (average age 59.0 ± 9.6 years) had an acute thalamic hemorrhage. Specific neurological features of clinical vascular syndromes of acute thalamic strokes in the lower lateral vascular territory were analyzed, compared, and described.

Keywords: thalamus; stroke; thalamic stroke; clinical features; syndrome; vascular territory; lower lateral vascular territory

Introduction

Worldwide, stroke is one of the leading global causes of death, long-term, and permanent disability [1–17]. Someone has a stroke every 40 seconds on average, and someone died of stroke every 3 minutes 42 seconds [10, 18, 19]. In addition, more young people are affected by stroke in low- and middle-income countries. Eastern Europe, East Asia, and parts of Southeast Asia, Central Asia, and sub-Saharan Africa had the highest rates of stroke mortality. Age-standardized prevalence rates of stroke were higher in Eastern Europe and East Asia [8, 20–22]. Thalamic strokes, both alone and in combination with strokes involving other structures, are not rare, accounting for approxi-

mately 11 to 23–25 % of all posterior circulation strokes, especially in combination with damage to other structures [23–25].

The thalamus manages our sensitivity to temperature, light, and physical touch. It controls the flow of visual, auditory, and motor information. The thalamus is also involved in aspects of learning, memory, speech, language understanding, motivation, attention and wakefulness, being in charge of our sense of balance and awareness of our arms and legs. It controls how we experience pain, even emotional experiences, expressions, and our personalities involve the thalamus. Neurological and neuropsychological symptoms of thalamic strokes are invariably investigated by medical

doctors during an objective examination of the patient, being an integral part of establishing a syndromological, topical, and clinical diagnosis.

However, currently, there are not enough published prospective hospital-based cohort studies that report and analyze pathophysiological features and patterns of the occurrence of neurological, neuropsychological, and clinical vascular syndromes of thalamic strokes in the lower lateral vascular territory, and their topical diagnosis using clinical, neurological, and neuroimaging methods in a prospective hospital-based cohort study [25–31].

The determination of vascular thalamic syndrome allows solving two main issues: the presence of damage to a specific vascular territory and a topical diagnosis of the central nervous system damage (thalamic stroke) [30]. Given all this, we performed a comprehensive clinical and neuroimaging analysis of the treatment results and assessed the outcome of the disease in 34 patients with thalamic stroke, among whom 22 people had an isolated thalamic infarction and 12 — hemorrhage in the thalamus.

The purpose of this study is to describe and analyze the clinical and neuroimaging features of vascular syndromes of thalamic strokes in the lower lateral vascular territory in a prospective hospital-based cohort study, providing a comprehensive clinical and neuroimaging analysis.

Materials and methods

The materials and methods of this prospective hospital-based cohort study of acute ischemic stroke patients were reported previously [29–31, 46]. In brief, only patients with MRI/CT-proven thalamic stroke aged 18 years or older formed a study group.

All study participants were admitted to the Neurological Center of Oleksandrivska Clinical Hospital (Kyiv, Ukraine) that consists of an admission department, clinical department of neurology, department of cerebrovascular pathology with intensive care/stroke unit, and a research department of neurology. Patients were admitted to the hospital within the first 24 h since the first stroke symptoms occurred. All stroke cases were reviewed by at least two board-certified neurologists with training in cerebrovascular diseases. Clinical history, 12-lead electrocardiogram, blood testing, carotid ultrasound, head computed tomography (CT) and/or brain magnetic resonance imaging (MRI) were obtained for all study participants. Stroke was defined according to criteria of the World Health Organization, American Heart Association/American Stroke Association guidelines for adult stroke, and was confirmed by neuroimaging [32, 33]. The etiology of stroke was classified according to the TOAST criteria [34]. The National Institutes of Health Stroke Scale, the Modified Rankin Scale, the Barthel index, and the Charlson Comorbidity Index were determined for all participants. Secondary stroke prevention was prescribed according to the American Heart Association/American Stroke Association and the European Stroke Organisation guidelines immediately after the stroke diagnosis was made [35–41]. Stroke education programs were provided to all study participants [11, 16, 30, 42–45].

Parametric and non-parametric statistic methods were applied. The log-rank test was used for univariate comparisons of event-free survival between groups. A two-sided $p < 0.05$ was considered significant for all analyses. All statistical analyses were performed using IBM SPSS Statistics Version 22.

Results and discussion

In total, 319 adult patients with an acute MRI/CT-proven stroke were screened from 2001 to 2011. Among them, 204 (63.9 %) individuals were diagnosed with an acute posterior circulation ischemic stroke, and 115 (36.1 %) had an intracerebral hemorrhage. A thalamic stroke was diagnosed in 34 (10.6 %) of 319 patients, forming a study group: 22 of them (12 men, 10 women aged 50–84 years; average age 61.9 ± 10.2 years) were diagnosed with an acute isolated thalamic stroke, and in the rest 12 patients (5 men, 7 women aged 57–75 years; average age 59.0 ± 9.6 years), a thalamic hemorrhage was detected (Fig. 1).

An isolated stroke in the lower lateral thalamic vascular territory manifested itself in heterolateral hemihypesthesia (in relation to the superficial types of sensitivity) and contralateral hemiataxia. Sensitivity impairments are often combined with impaired motor skills due to damage to the tissue of the internal capsule adjacent to the stroke foci, which determines the development of the sensorimotor syndrome.

In patients with extensive lower lateral thalamic stroke, the classic thalamic Dejerine-Roussy syndrome or thalamic pain syndrome occurs that is characterized by moderate contralateral hemiparesis, hemihypesthesia, hemiataxia, hemialgia, paresthesia, as well as dysesthesia (perversion of the perception of sensitive irritations). This syndrome was first described in detail by the French neurologist Joseph Jules Dejerine and his student Gustave Roussy in 1906. Thalamic syndrome was revealed in two patients with an extensive ischemic stroke of the lower lateral territory, being characterized by the following clinical manifestations: moderate transient hemiparesis on the side opposite to the lesion without signs of muscle spasticity, severe hemihypesthesia, hemiataxia, pain and paresthesia after a stroke in the distal extremities, often extending to the entire half of the body, — hemialgia.

In patients with extensive lesions in the lower lateral vascular territory of the thalamus, a dynamic contracture of the fingers can occur in the side opposite to a stroke, so-called classic thalamic arm (main thalamic) that is described as follows: the forearm is bent and pronated, the wrist joint is bent, the proximal phalanges of the fingers are moderately bent, while the middle and distal phalanges are fully extended. The fingers of the hand are in continuous motion — it is hyperkinesis of the choreoathetoid type [30]. The described clinical syndrome occurs as a result of damage to the ventral posterior and ventral lateral thalamic nucleus with the spread of the infarction focus to the internal capsule. Pain and dysesthesia that are typical for Dejerine-Roussy syndrome give a reason to believe that at the level of specific nuclei of the thalamus, there is not

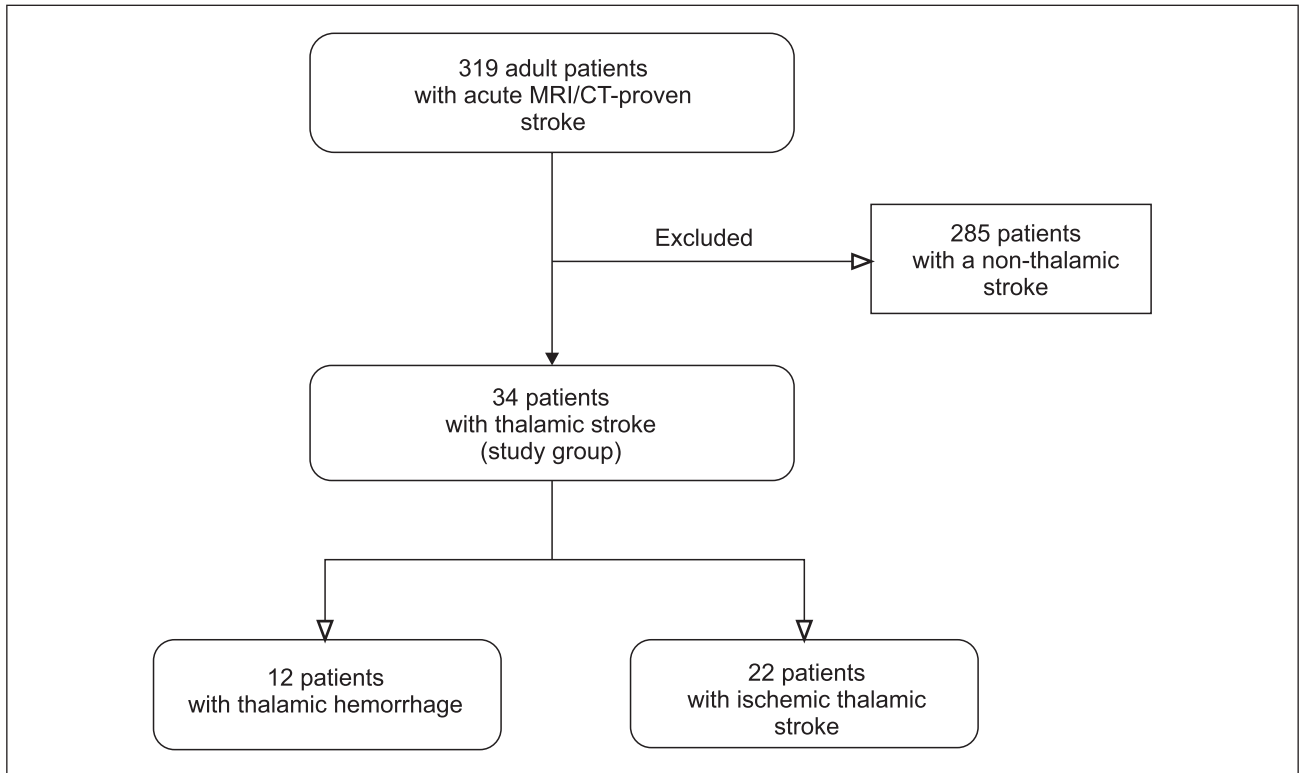


Figure 1. Case selection flowchart

just a switching of impulses for further transmission to the cerebral cortex, but the primary processing of information is carried out with the formation of primitive sensations. With a stroke in the lower lateral thalamic territory, foci of excitation arise that, along with the participation of association nuclei, causes the appearance of non-localized, diffuse burning (protopathic) pains, paresthesia.

Neurological symptoms in patients with stroke of the lower lateral thalamic territory can mimic symptoms of ischemic stroke with capsular localization of the lesion (carotid arterial systems). Thalamic pain with all signs of hyperpathia, emotional and autonomic manifestations is pathognomonic for thalamic stroke. In clinical practice, thalamic syndrome is associated with hemianesthesia, hemiataxia, and hemianopsia even though these symptoms are not pathognomonic for thalamic stroke. In addition to the sensitive ones, it is important to consider the presence of hemialgia, paresthesia, psychosensory impairment (hallucinoses), choreoathetoid hyperkineses, dystonic manifestations with a tendency to contractures of a dynamic type, and emotional central paresis of facial muscles. In all patients with infarction of the lower lateral thalamic territory, varying degrees of impaired cognitive status were present. The most significant cognitive impairment was in patients with Dejerine-Roussy syndrome.

In our study, 9 (40.9 %) of 22 patients developed an isolated thalamic stroke that was localized in the lower lateral classical territory that is vascularized by the lower lateral, or thalamogeniculate, arteries. The main clinical manifestation in all patients was impaired surface sensitivity of varying degrees on the contralateral

half of the body. Hemihypesthesia in 6 (66.7 %) people was combined with bathyhypesthesia and contralateral hemiataxia. In 7 (77.8 %) patients, the infarcted lesion spread to the adjacent internal capsule, causing the development of the sensorimotor syndrome on the side opposite to the lesion. At the same time, in 2 individuals, motor disorders were preceded by sensitivity disorders (sensorimotor stroke), in the rest 5 patients, motor and sensory disorders coincided in time. In 4 patients with left-sided lesions of the lower lateral area of the thalamus, the emotional sphere disorders of varying severity and various manifestations of dysthymia (longing, apathy, fear) were noted.

The most common causes of a thalamic stroke in the lower lateral territory were microangiopathies in patients with arterial hypertension and hypercholesterolemia ($n = 5$), diabetes mellitus ($n = 2$), cardioembolism ($n = 2$).

Conclusions

Isolated stroke of the lower lateral thalamic vascular territory manifested itself in a syndrome of heterolateral hemianesthesia, hemiataxia, combined with impaired motor skills, the presence of pain, autonomic disorders with signs of hyperpathia, cognitive deficit; a specific sign is the development of Dejerine-Roussy syndrome; with an extensive lesions in the contralateral side, a dynamic contracture of the fingers can occur — the classic thalamic arm (main thalamique); the spread of a stroke to the adjacent inner capsule causes the development of sensorimotor syndrome.

Conflicts of interests. Authors declare the absence of any conflicts of interests and their own financial interest that might be construed to influence the results or interpretation of their manuscript.

Additional information

Role of the funding source — none

Disclosures — none

Author contributions

S.M. Vynychuk — study concept and design, statistical analysis, interpretation of data, literature overview, critical revision of the manuscript for important intellectual content; *M.M. Prokopiv* — study concept and design, data acquisition, statistical analysis, interpretation of data, literature overview, critical revision of the manuscript for important intellectual content; *L.M. Trepet* — study design, data acquisition, statistical analysis, interpretation of data; *O.Ye. Fartushna* — study concept and design, literature overview, statistical analysis, interpretation of data, article concept and design, drafting the article, critical revision of the manuscript for important intellectual content.

References

1. Benjamin E.J., Muntner P., Alonso A. [et al.]. On behalf of the American Heart Association Council on Epidemiology and Prevention Statistics Committee and Stroke Statistics Subcommittee. Heart disease and stroke statistics — 2019 update: a report from the American Heart Association. *Circulation*. 2019. Vol. 139(10). P. e56-e528.
2. Johnson W., Onuma O., Owolabi M., Sachdev S. Stroke: a global response is needed. *Bulletin of the World Health Organization*. 2016. Vol. 94. P. 634-634A.
3. Vynychuk S.M., Fartushna O.Ye. Cerebrospinal and commissural diaschisis in acute stroke patients: case analysis. *Mezhdunarodnyy nevrologicheskij zhurnal*. 2018. № 5(99). С. 20-25.
4. Fartushna O.Ye., Vynychuk S.M. Brain injury in patients with acute TIA: clinical features in different TIA subtypes. *Mezhdunarodnyy nevrologicheskij zhurnal*. 2017. № 3(89). С. 13-18.
5. Feigin V.L., Norrving B., Mensah G.A. Global burden of stroke. *Circulation research*. 2017. Vol. 120(3). P. 439-448.
6. Global Health Estimates. Geneva: World Health Organization; 2012. Режим доступу: http://www.who.int/healthinfo/global_burden_disease/en/.
7. Lees R., McGrane F., Fartushna O., Broomfield N.M., Quinn T.J., Dani K., Forbes K., Dawson J. Vascular cognitive impairment/vascular dementia. The pattern of cognitive impairment in stroke survivors with carotid stenosis. *International Journal of Stroke*. 2014. Vol. 9. P. 323-324.
8. Owolabi M.O., Akarolo-Anthony S., Akinyemi R. [et al.]. The burden of stroke in Africa: a glance at the present and a glimpse into the future. *Cardiovasc. J. Afr.* 2015. Vol. 26(2). Suppl. 1. P. S27-38.
9. Wilkins E., Wilson L., Wickramasinghe K. [et al.]. European cardiovascular disease statistics 2017. Brussels: European Heart Network, 2017. 188 p.
10. World Stroke Organization. Global Stroke Fact Sheet. 26.02.2019. Режим доступу: https://www.world-stroke.org/images/WSO_Global_Stroke_Fact_Sheet_final.pdf.
11. Віничук С.М., Прокопів М.М. Гострий ішемічний інсульт. Київ: Наукова думка, 2006. 286 с.
12. Віничук С.М., Фартушина О.Є. Рання реабілітація після гострих ішемічних порушень мозкового кровообігу. *Міжнародний неврологічний журнал*. 2016. № 8(86). С. 34-39.
13. Евтушенко С.К., Филлимонов Д.А., Евтушенко И.С. Новые факторы риска развития инсульта у лиц молодого возраста. *Журнал неврологии и психиатрии им. С.С. Корсакова. Спецвыпуск*. 2015. Т. 115. № 12. С. 3-12.
14. Фартушина О.Є., Прокопів М.М. Актуальність проблеми цереброваскулярних захворювань, транзиторних ішемічних атак та вдосконалення їх діагностики в системі охорони здоров'я в Україні. *Проблеми військової охорони праці: [Зб. наук. праць Української військово-медичної академії. За ред. проф. Білого В.Я.]. Київ: УВМА, 2007. Вип. 19. С. 335-342.*
15. Фартушина О.Є., Віничук С.М. Виявлення та усунення васкулярних чинників ризику важливий напрямок первинної профілактики транзиторних ішемічних атак та/чи інсульту. *Український медичний часопис*. 2015. № 1(105). С. 23-27.
16. Фартушина О.Є., Віничук С.М. Транзиторні ішемічні атаки. Київ: ВД «Авіцена», 2014. 216 с.
17. Feigin V.L., Nguyen G., Cercy K. [et al.]. GBD 2016 Lifetime Risk of Stroke Collaborators. Global, regional, and country-specific lifetime risks of stroke, 1990 and 2016. *N. Engl. J. Med.* 2018. Vol. 379(25). P. 2429-2437.
18. Institute for Health Metrics and Evaluation (IHME). Findings from the Global Burden of Disease Study 2017. Seattle, W.A.: IHME, 2018.
19. World Stroke Organization. Facts and Figures about Stroke. Режим доступу: <http://www.world-stroke.org/component/content/article/16-forpatients/84-facts-and-figures-about-stroke>.
20. GBD 2016 Causes of Death Collaborators. Global, regional, and national age-sex specific mortality for 264 causes of death, 1980–2016: a systematic analysis for the Global Burden of Disease Study 2016. *Lancet (London, England)*. 2017. Vol. 390(10100). P. 1151-1210.
21. Wang H., Naghavi M., Allen C. [et al.]. Global, regional, and national life expectancy, all-cause mortality, and cause-specific mortality for 249 causes of death, 1980–2015: a systematic analysis for the Global Burden of Disease Study 2015. *Lancet*. 2016. Vol. 388(10053). P. 1459-1544.
22. Фартушина О.Є., Віничук С.М. Епідеміологія транзиторних ішемічних атак в структурі гострих порушень мозкового кровообігу в Україні та інших країнах. *Міжнародний неврологічний журнал*. 2017. № 5(91). С. 105-111.
23. Chen X.Y., Wang Q., Wang X. et al. Clinical features of thalamic stroke. *Curr. Treat. Options Neurol.* 2017. Vol. 19(2). P. 5.
24. Віничук С.М., Ялынская Т.А., Віничук И.С. Инфаркты в вертебробазиллярном бассейне: клиника и диагностика. *Международ. неврол. журн.* 2005. № 3. С. 13-21.
25. Lopez-Serna R., González-Carmona P., López-Martínez M.J. Bilateral thalamic stroke due to occlusion of the artery of Percheron in a patient with patent foramen ovale: a case report. *Med. Case Reports*. 2009. Vol. 3. P. 7392.
26. Bogousslavsky J., Regli F., Uske A. Thalamic infarcts: clinical syndromes, etiology, and prognosis. *Neurology*. 1988. Vol. 38(6). P. 837-48.
27. Cheng H., Tian Y., Hu P., Wang J., Wang K. Time-based prospective memory impairment in patients with thalamic stroke. *Behavioral Neuroscience*. 2010. Vol. 124(1). P. 152-158.

28. Steinke W., Sacco R.L., Mohr J.P. [et al.]. Thalamic stroke. Presentation and prognosis of infarcts and hemorrhages. *Arch. Neurol.* 1992. Vol. 49. P. 703-710.
29. Виничук С.М., Прокопів М.М., Трепет Л.Н. Изолированный инфаркт таламуса: клинические синдромы, диагностика, лечение и исход. *Український медичний часопис.* 2012. № 2. С. 87-93.
30. Виничук С.М., Прокопів М.М., Трепет Л.Н. Таламические инсульты; *Нац. мед. ун-т им. А.А. Богомольца, Александр. клинич. б-ца, г. Киев, Украина. Киев: Агат-Принт, 2018. 91 с.: ил. Библиогр.: с. 82-91.*
31. Vynychuk S.M., Prokopiv M.M., Trepet L.M., Fartushna O.Y. Thalamic stroke outcomes: a prospective hospital-based cohort study. *Meždunarodnyj nevrološkičeskij žurnal.* 2019. № 8(110). P. 23-27.
32. Kernan W.N., Ovbiagele B., Black H.R. [et al.]. Guidelines for the prevention of stroke in patients with stroke and transient ischemic attack: a guideline for healthcare professionals from the American Heart Association/American Stroke Association. *Stroke.* 2014. Vol. 45. P. 2160-2236.
33. Aho K., Harmsen P., Hatano S. [et al.]. Cerebrovascular disease in the community: results of a WHO collaborative study. *Bull. World Health Organ.* 1980. Vol. 58. P. 113-130.
34. Adams H.P., Bendixen B.H., Kappelle L.J. [et al.]. Classification of subtype of acute ischemic stroke. Definitions for use in a multicenter clinical trial. TOAST. Trial of Org 10172 in Acute Stroke Treatment. *Stroke.* 1993. Vol. 24. P. 35-41.
35. Ringleb P., Schellinger P.D., Hacke W. [et al.]. [European Stroke Organisation 2008 guidelines for managing acute cerebral infarction or transient ischemic attack. Part 1]. *Der Nervenarzt.* 2008. Vol. 79. P. 936-957.
36. Adams R., Albers G., Alberts M. [et al.]. Update to the AHA/ASA Recommendations for the Prevention of Stroke in Patients with Stroke and Transient Ischemic Attack. *Stroke.* 2008. Vol. 39. P. 1647-1652.
37. Fartushna O.Y. Emergency therapeutic approach as a secondary prevention of an acute ischemic stroke in patients with TIA. XX World Neurological Congress, 12-17.11.2011. Marrakesh, Morocco, 2011. P. 167.
38. Fartushnaya E.E., Vinichuk S.M. Reducing the risk of recurrent ischemic stroke, after transient ischaemic attack along with neuroprotective and antiaggregant therapy. XIV International Congress of Rehabilitation Medicine and Immunorehabilitation, 16-21.10.2009: abstract. Tel-Aviv, Israel, 2009. P. 67.
39. Виничук С.М., Фартушина О.Є. Диференційоване лікування транзиторних ішемічних атак — ефективний спосіб профілактики повторних гострих церебральних подій. *Міжнародний неврологічний журнал.* 2014. № 6. С. 87-92.
40. Виничук С.М., Фартушина О.Є. Аторвастатин та його роль у профілактиці та лікуванні ішемічних порушень мозкового кровообігу. *Здоров'я України.* 2015. № 9. С. 3.
41. Фартушина О.Є., Виничук С.М. Використання оптимальної дози препарату Торвакард — важливий напрямок зниження ризику розвитку повторних транзиторних ішемічних атак та/чи інсульту. *Семейная медицина.* 2015. № 3. С. 223-227.
42. Виничук С.М., Фартушина О.Є. Рання реабілітація після гострих ішемічних порушень мозкового кровообігу. *Міжнародний неврологічний журнал.* 2016. № 8(86). С. 34-39.
43. Виничук С.М., Фартушина О.Є. Освітні програми профілактики транзиторних ішемічних атак та/чи інсульту. *Укр. мед. часоп.* 2014. № 5. С. 49-51.
44. Фартушина О.Є., Виничук С.М. Модифікація поведінкових чинників ризику як складова первинної профілактики транзиторних ішемічних атак та/чи інсульту. *Український медичний часопис.* 2014. № 6(104). XI/XII. С. 42-44.
45. Фартушина О.Є. Патогенетичні підтипи транзиторних ішемічних атак: особливості неврологічної клініки, гемодинаміки та лікування [Текст]: Дис... канд. мед. наук: 14.01.15. Фартушина Олена Євгенівна; *Нац. мед. ун-т ім. О.О. Богомольця. Київ, 2012. 217 арк.: рис., табл. Библиогр.: арк. 187-217.*
46. Vynychuk S.M., Prokopiv M.M., Trepet L.M., Fartushna O.Y. Clinical vascular syndromes of thalamic strokes in anterior and paramedian vascular territories: a prospective hospital-based cohort study. *Meždunarodnyj nevrološkičeskij žurnal.* 2020. Vol. 2(16). P. 15-20.

Received 04.01.2020

Revised 28.01.2020

Accepted 08.02.2020 ■

Виничук С.М.¹, Прокопів М.М.², Трепет Л.М.¹, Фартушина О.Є.³¹Олександрівська клінічна лікарня, м. Київ, Україна²Національний медичний університет ім. О.О. Богомольця, м. Київ, Україна³Українська військово-медична академія, м. Київ, Україна

Клінічні синдроми таламічних інсультів нижньолатеральної судинної території: проспективне клінічне когортне дослідження

Резюме. Актуальність. У статті проаналізовано і описано патофізіологічні особливості й закономірності виникнення неврологічних, нейропсихологічних та клінічних судинних синдромів таламічних інсультів нижньолатерального судинного басейну. **Мета дослідження:** описати і проаналізувати клініко-нейровізуалізаційні особливості судинних синдромів таламічних інсультів нижньолатеральної судинної території в проспективному клінічному когортному дослідженні. **Матеріали та методи.** Ми провели проспективне клінічне когортне дослідження 319 пацієнтів із гострим інсультом, які надійшли до неврологічного центру Олександрівської клінічної лікарні (м. Київ, Україна) протягом перших 24 годин з моменту розвитку інсульту. Усі пацієнти пройшли комплексне клініко-неврологічне, лабораторне, ультразвукове і нейровізуалізаційне обстеження. **Результати.** Серед 319 хворих із гострим інсультом нейровізуалізаційно підтверджений таламічний інсульт діагностовано в 34 (10,6 %) пацієнтів. Із них у 22 осіб (середній вік 61,9 ± 10,2 року) виявлено гострий ізольований інфаркт таламуса, а в 12 (середній вік 59,0 ± 9,6 року) — гострий таламічний крововилив. Проаналізовані, порівняні та описані специфічні неврологічні особливості клінічних судинних синдромів гострих таламічних інсультів нижньолатеральної судинної території.

Ключові слова: таламус; інсульт; таламічний інсульт; клінічні особливості; синдром; судинна територія; нижньолатеральна судинна територія

Виничук С.М.¹, Прокопів М.М.², Третет Л.Н.¹, Фартушная Е.Е.³

¹Александровская клиническая больница, г. Киев, Украина

²Национальный медицинский университет им. А.А. Богомольца, г. Киев, Украина

³Украинская военно-медицинская академия, г. Киев, Украина

Клинические синдромы таламических инсультов нижнелатеральной сосудистой территории: проспективное клиническое когортное исследование

Резюме. Актуальность. В статье проанализированы и описаны патофизиологические особенности и закономерности возникновения неврологических, нейропсихологических и клинических сосудистых синдромов таламических инсультов нижнелатерального сосудистого бассейна. **Цель исследования:** описать и проанализировать клинико-нейровизуализационные особенности сосудистых синдромов таламических инсультов нижнелатеральной сосудистой территории в проспективном клиническом когортном исследовании. **Материалы и методы.** Мы провели проспективное клиническое когортное исследование 319 пациентов с острым инсультом, поступивших в неврологический центр Александровской клинической больницы (г. Киев, Украина) в течение первых 24 часов с момента развития инсульта. Все пациенты прошли комплексное

клинико-неврологическое, лабораторное, ультразвуковое и нейровизуализационное обследования. **Результаты.** Среди 319 больных с острым инсультом нейровизуализационно подтвержденный таламический инсульт диагностирован у 34 (10,6 %) пациентов. Из них у 22 человек (средний возраст $61,9 \pm 10,2$ года) обнаружен острый изолированный инфаркт таламуса, а у 12 (средний возраст $59,0 \pm 9,6$ года) — острое таламическое кровоизлияние. Проанализированы, сравнены и описаны специфические неврологические особенности клинических сосудистых синдромов острых таламических инсультов нижнелатеральной сосудистой территории.

Ключевые слова: таламус; инсульт; таламический инсульт; клинические особенности; синдром; сосудистая территория; нижнелатеральная сосудистая территория

Review of the manuscript

"Clinical syndromes of a thalamic stroke in the lower-lateral vascular territory: a prospective hospital-based cohort study" submitted to the "International Neurological Journal" (Ukraine)

The article is actual, well presented and structured, is based on a relevant amount of participants with the up to date diagnostic approach (319 adult patients with an acute MRI/CTi proven stroke were screened). The authors described a neurological, topical and clinical neuroimaging diagnostic of thalamic strokes in the lower lateral vascular territory from modern positions. The functional anatomy and physiology of the thalamus and the lower lateral thalamic vascular territories are deeply described. The literature overview is based on latest information. However, the presented overview is too broad and is suggested to be shorted and summarized. The clinical manifestations of vascular syndromes of the thalamus are well described. Notably, that particular attention is paid to the coverage of modern approaches to the diagnostic and management of patients with a thalamic stroke. References are consists of a large number of foreign articles, but more references to the Ukrainian authors is suggested to add.

Considering some minor and not essential listed above pros, that are perfectly and promptly addressed by the authors, overall, article is written and presented well. It is bringing an important impact in the medicine and is highly suggested to be published.

With kind regards, Colin D. Ferrie (Scotland, UK)