



Ukrainian Journal of Nephrology and Dialysis

Scientific and Practical, Medical Journal

Founders:

- State Institution «Institute of Nephrology NAMS of Ukraine»
- National Kidney Foundation of Ukraine

ISSN 2304-0238;
eISSN 2616-7352

Journal homepage: <https://ukrjnd.com.ua>

Nephrology School

Ivana P. Dewi^{1,2}, Kristin P. Dewi^{1,2}, N. Mardiana^{1,3}

doi: 10.31450/ukrjnd.2(66).2020.05

Renal artery stenosis: the challenging in diagnosis and therapy

¹ Faculty of Medicine, University Airlangga, Surabaya, Indonesia

² Faculty of Medicine, Duta Wacana Christian University, Yogyakarta, Indonesia

³ Nephrology and Hypertension Division, Departement of Internal Medicine, Dr. Soetomo General Hospital, Surabaya, Indonesia

Citation:

Ivana P. Dewi, Kristin P. Dewi, N. Mardiana. Renal artery stenosis: the challenging in diagnosis and therapy. Ukr J Nephrol Dial. 2020;2(66):32-39. doi: 10.31450/ukrjnd.2(66).2020.05

Article history:

Received February 05, 2020

Received in revised form

February 08, 2020

Accepted March 02, 2020

Abstract. Hypertension is still the most prevalent non-communicable diseases in Indonesia. Renovascular hypertension is one type of secondary hypertension. It is commonly caused by the presence of renal artery stenosis (RAS). Whereas, atherosclerosis (ARAS) and fibromuscular disease (FMD) are the most common causes of RAS. Early diagnosis is necessary because it has the potential to be cured by eliminating stenosis of the renal artery. However, the signs and symptoms of renovascular hypertension are not specific. The supporting examination to diagnose RAS is also expensive. So, screening in the population at risk is needed. The examinations to prove the presence of RAS are arteriography, captopril renogram, renal ultrasonography, renal Doppler ultrasonography, magnetic resonance angiography (MRA), and computed angiographic tomography (CTA).

Until now, three therapeutic modalities can be selected in the management of renovascular hypertension; pharmacological therapy, surgical intervention, percutaneous intervention angioplasty with and without stenting. This narrative review summarizes the literature focused on the diagnosis and therapy of RAS.

Keywords: renal artery stenosis, diagnosis, therapy.

Conflict of interest statement: the authors declared no competing interests.

© Ivana P. Dewi, Kristin P. Dewi, N. Mardiana, 2020. All rights reserved.

Correspondence should be addressed to Ivana P. Dewi dr_ivanapd@staff.ukdw.ac.id



© Деві І. П., Деві К. П., Мардіана Н., 2020.

УДК: 616.136.7:616.61]-07-085

Івана П. Деві^{1,2}, Крістін П. Деві^{1,2}, Н. Мардіана^{1,3}

Стеноз ниркової артерії: складне діагностичне та терапевтичне завдання

¹Медичний факультет університету Ерланга, Сурабая, Індонезія

²Медичний факультет Християнського університету Дута Вакана, Джокарта, Індонезія

³Відділення нефрології та гіпертонії відділу внутрішньої медицини, головного госпіталю ім. Соетомо, Сурабая, Індонезія

Резюме. Артеріальна гіпертензія є найпоширенішим неінфекційним захворюванням в Індонезії. Реноваскулярна гіпертензія зазвичай викликана наявністю стенозу ниркової артерії (СНА). В той час, як атеросклероз та фіброзно-м'язова хвороба є найпоширенішими причинами СНА. Однак ознаки та симптоми реноваскулярної гіпертензії не є специфічними, а діагностичні методи – високоартисні. Існуючі на сьогодні методи дослідження щодо підтвердження наявності СНА включають: артеріографія, каптоприл-ренограма, ниркова ультрасонографія, доплерографія, магнітно-резонансна ангіографія та комп'ютерна ангіографічна томографія.

На сьогодні запропоновано 3 терапевтичні стратегії лікування реноваскулярної гіпертензії: фармакологічна терапія, хірургічне втручання, черезшкірна інтервенційна ангіопластика з та без стентування. Цей наративний огляд узагальнює наукову літературу, зосереджену на сучасних підходах до діагностики та лікування СНА.

Ключові слова: стеноз ниркової артерії, діагностика, лікування.

Introduction. Hypertension is a disease that has the highest prevalence of non-communicable diseases in Indonesia. Hypertension can be divided into essential or primary hypertension and secondary hypertension. The cause of essential hypertension is unknown and covers 90-95% of hypertension cases. The other 5-10% is secondary hypertension. Secondary hypertension is hypertension that has clear pathophysiology, and in some cases, has specific clinical and laboratory manifestation [1]. Renovascular hypertension is one form of secondary hypertension. It causes the most secondary hypertension. There are strong indications to diagnose secondary hypertension because this type of hypertension could be removed with a particular procedure or intervention surgery [2].

Renovascular hypertension is defined as the sudden enhancement of blood pressure as a consequence of various conditions relating to the main renal arteries or its branches. The prevalence of renovascular hypertension is 1-4% in all hypertension population [3]. Diagnosis of renovascular hypertension is often missed, even though this type of hypertension can be handled and cured at all ages. However, if this hypertension is not immediately treated, then there is less possibility to eliminate the etiology and control the blood pressure if kidney nephrosclerosis has already happened [4].

Etiology. The most common etiology of renovascular hypertension is renal artery stenosis (RAS), kidney parenchymal disease, or a combination of them. RAS happens when there is a narrowing of one or both

of the renal arteries and its branches that will cause renal ischemia. Most people with RAS are asymptomatic because the blood flow to the kidney is still adequate. However, in some individuals, it will manifest as hypertension with or without disturbance in renal function. Generally, stenosis of 60-70% will cause consequences of hypoperfusion and renal ischemia that induce renovascular hypertension conditions [4]. Various pathological circumstances, such as minor or significant lesions can cause RAS. Two major causes of RAS are atherosclerosis artery renalis (ARAS) and fibromuscular dysplasia (FMD). While the minor lesions that are known to play a role in RAS include; Takayasu arteritis, polyarteritis nodosa, aortic dissection, radiation arteritis, and embolism [5].

Atherosclerosis artery renalis (ARAS) is the most common form of RAS, and it accounts for 80-90% of this condition. ARAS commonly happens in the male and geriatric populations. In the ages of more than 50 years in the population, atherosclerotic lesions in the renal arteries cause 60% of RAS [6]. Atherosclerosis lesions in renal arteries are rarely found in older women with an age less than 50 years or in women who have not yet gone through menopause. Some risk factors could influence and stimulate the formation of the atherosclerotic lesion.

The risk factors can be divided into modifiable and non-modifiable risk factors. Modifiable risk factors are smoking, hypercholesterolemia, hypertension, diabetes mellitus, and obesity. While the non-modifiable risk factors are old age, being male, and having a family history of atherosclerosis disease. The predilection of the atherosclerotic lesion usually constricts the lumen of the one-third proximal renal artery. Ostium can be involved in about 75% of cases. Narrowing of arterial lumen up to 75% is associated with a significant decline

Ivana P. Dewi

dr_ivanapd@staff.ukdw.ac.id

of glomerular filtration rate (GFR). ARAS can worsen over time, causing hypertension and chronic kidney disease [2].

More rarely, about 10-20% RAS can be caused by fibromuscular dysplasia (FMD), which are fibrous changes in two-third distal renal arteries and intrarenal branches. FMD is usually bilateral. These fibrous changes influence the tunica media artery renalis (65-75%). FMD has a typical stenotic area alternating with widening aneurysms (a string of pearls) in the distal renal artery which sometimes extends to the branches of the main renal artery. The cause of FMD is not fully known yet. Genetic factors and smoke habit suspected as factors that can improve the possibility someone suffers from these abnormalities. FMD is usually seen in women and young age (40-80%). FMD is more commonly found in the Caucasians compared to African Americans or in Asian populations [3].

Renovascular hypertension pathophysiology is related directly with declining kidney perfusion that arises as a consequence of RAS existence. Kidney hypoperfusion will cause renal ischemia that activates the renin-angiotensin-aldosterone (RAA) system. The kidney baroreceptor adapts with the increased release of renin from the juxtaglomerular apparatus to the systemic circulation. This condition will cause the formation of angiotensin II. Angiotensin II will mediate vasoconstriction to maintain blood flow in the stenosis artery. Vasoconstriction mainly occurs in efferent arterioles of glomerulus to preserve GFR even though kidney perfusion decreases. Angiotensin II also stimulates aldosterone secretion from the adrenal cortex that plays a role in fluid and sodium retention [7].

There are differences between renovascular hypertension pathophysiology caused by stenosis in one kidney and two kidneys. Two of Goldblatt's model experiments explained it (Figure 1). The first model is two kidney – one clip hypertension. Stenosis of artery renalis happens only on one side and kidney contralateral is still intact. This condition will increase renin activity that stimulates the production of angiotensin II. Angiotensin II is a potent vasoconstrictor. So, in this stage, the hypertension is renin-angiotensin dependent. Increasing of angiotensin II will stimulate the adrenal cortex to release aldosterone that causes sodium and water retention. Salt and water retention results in a decline in renin production. At this stage, hypertension is volume dependent. On another side, kidney contralateral will increase the excretion of sodium (pressure natriuresis) and prevent the occurrence of overload syndrome. In the two kidney – one clip model, administration of Angiotensin-Converting Enzyme inhibitors (ACEI) will give a significant hypotension effect because there is hyperreninemia condition. The second experiment is one kidney one – clip hypertension. Renal arteries are experiencing stenosis bilateral or unilateral stenosis in a solitary kidney. In this condition, hypertension occurs because no diuresis pressure and natriuresis pressure is resulting in salt and air retention rapidly (volume expansion). This condition gives rise to feedback on barriers to renin production, so generally, renin levels become normal or low. Therefore in the one kidney - one clip hypertension model, the administration of ACEI, does not have a hypotensive effect [8].

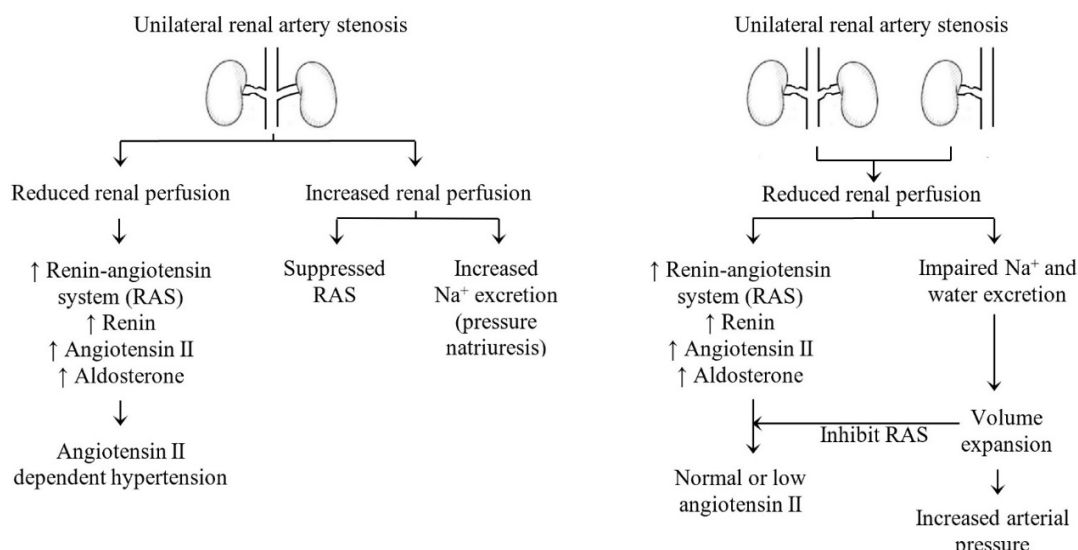


Fig. 1. Goldblatt hypertension models [7].

Correcting RAS will restore blood pressure into normal values. However, in some cases, blood pressure still increases, while plasma renin and aldosterone levels begin to decline into normal value. So that at the lat-

er stage, the correction of stenosis is not able to restore blood pressure. It is because there are already renal tubular atrophy and extensive interstitial fibrosis due to a prolonged state of hypoperfusion. Likewise, in the

contralateral kidney, a long period of intraglomerular hypertension may cause proteinuria and glomerulosclerosis that result in extensive damage to the nephrons.

Diagnosis. Clinical manifestations of RAS are often asymptomatic and are found incidentally during general check-ups. RAS needs to be suspected in children, adolescents, young women, men with atherosclerosis risk factors (smoking or having dyslipidemia), and a history of vascular occlusions, such as coronary heart disease, stroke, peripheral vascular occlusion, and aortic aneurysm abdominal if they suffer from hypertension [9]. Signs and symptoms of RAS are usually not specific and are often associated with target organs that are affected by hypertension. Headache, changes in consciousness, blurred vision, and vomiting are common symptoms. ARAS can be asymptomatic or can manifest and cause hypertension, ischemic nephropathy, or both. To diagnose RS, from the anamnesis we can get information such as;

- Abrupt onset of hypertension with fast progression from mild to severe,
- The onset of HT<30 years without familial history of severe HT >55 years,
- Hypertension w/ recurrent pulmonary edema,
- Resistant hypertension with 3 or more antihypertension drugs in optimal dose,
- Hypertension with worsening of renal function after ACEI or Angiotensin Receptor Blocker (ARB) therapy,
- Hypertension with a history of occlusive vascular disease: CAD, stroke, peripheral

occlusive vascular disease, abdominal aorta aneurysm [3].

Hypertension that cannot be controlled with drugs will disrupt the function of both kidneys due to a lack of blood supply (ischemic nephropathy). In some patients, acute pulmonary edema can occur due to sudden heart failure in the left ventricle. FMD does not cause ischemic nephropathy or pulmonary edema [4].

From physical examination to the diagnosis of RAS, abdominal bruit, pain in the flank area, retinopathy, and pulses deficit are commonly found. Abdominal bruits found in the epigastrium or upper quadrant are important diagnostic features. From laboratory results, it can be found that hypokalemia is caused by increased renin activity (secondary aldosteronism) and increased serum creatinine levels caused by ischemic nephropathy [2].

The gold standard diagnostic tool for the diagnosis of RAS is the arteriography of artery renalis. Arteriography can show atherosclerotic characteristics and the location of RAS. Arteriography is needed if the patient will undergo angioplasty and stent placement. The limitations of renal arterial arteriography are an expensive and invasive procedure. Arteriography also does not provide information about the functional significance value of the lesion. Because of these limitations, other more new examination modalities have been developed including captopril renogram, renal ultrasonography (USG renal), renal Doppler ultrasonography (USG Doppler), magnetic resonance angiography (MRA), computed angiographic tomography (CTA). The sensitivity, specificity, advantages, and limitations of every modality are described in Table 1.

Table 1

Modalities to Diagnose Renal Artery Stenosis

Modality	Sensitivity	Specificity	Advantages	Limitation
Arteriography	Gold standard	Gold standard	evaluate the characteristic of RAS	expensive, invasive, does not provide a functional significance value of the lesion
Captopril Renography	79%	82%	evaluate GFR and renal perfusion	lack of anatomical info
USG Renal/ Doppler	82-98%	62-99%	easy to be found in many health facilities	↓ quality of imaging in the obese patient and depends on operator skills
CTA	86%	94%	detect stenosis that can't detect with USG	use iodine as contrast media (nephrotoxic)
MRA	88%	88%	can detect small stenosis, direct visualization of renal artery without contrast media, evaluate blood flow velocity, GFR, and renal perfusion	Not readily available in many health facilities

Captopril renogram is a screening modality with a nuclear technique that aims to evaluate the GFR and perfusion of each kidney. Patients should be well hydrated before the examination. Captopril 25-50mg was given to inhibit angiotensin I conversion to angiotensin II. In the process, the patient is monitored with a gamma camera. Blood pressure and pulse are monitored every 15 minutes for 1 hour. Captopril will cause efferent vasoconstriction to disappear and reduce intraglomerular pressure resulting in decreasing in GFR. The results of the examination can be interpreted as renovascular hypertension if there is a decrease in GFR in the arteries undergoing stenosis [10].

Renal ultrasonography can measure kidney size and structure, while USG Doppler can assess abnormalities of renal arterial blood flow. USG Doppler is an examination that is easily found in various health facilities compared to other modalities. The diagnosis of RAS can be established through USG Doppler by assessing the renal-aorta ratio (RAR) and peak systolic velocity (PSV) (Table 2).

Table 2

USG Doppler to assessing Renal Artery Stenosis [12]

Stenosis Degree	PSV	RAR
Normal	< 180 cm/s	< 3,5
<60%	> 180 cm/s	< 3,5
>60%	> 180 cm/s	> 3,5
Occlusion	No flow	can't be assess

RAS can be enforced if the degree of stenosis is more than 60% [11]. From USG Doppler, we can also calculate Resistance Index (RI) as a prognostic value when RAS is to be revascularized. RI > 80 indicates no benefit after revascularization.

CTA is an imaging study to visualize arterial anatomy. The disadvantage of CTA is the use of iodine contrast media that is nephrotoxic to produce 3-D imaging of the kidneys and blood vessels. MRA is a non-invasive technique that can show vascular anatomy and physiological information from renal function. MRA can visualize arteries directly without contrast agents, blood flow rates, GFR, and perfusion. CTA and MRA can detect small levels of stenosis from renal Doppler ultrasound. The American College of Radiology Association recommends MRA or CTA as a supporting modality for normal kidney function. In patients with kidney disorders, the modalities chosen are Doppler USG or MRA, followed by a captopril renogram [13].

Because unclear signs and symptoms and examinations to prove the presence of RAS are very expensive and are also not always available in all health facilities, screening to look at the possibility of RAS is necessary. Screening should be done in groups of hypertensive patients who have a history and clinical features with suspicion of a RAS, such as:

1. The low index of clinical suspicion
 - Borderline and mild hypertension without hypertensive target-organ damage

2. Moderate index of clinical suspicion
 - Severe hypertension (diastolic blood pressure (DBP) > 120 mmHg)
 - Refractory hypertension to standard therapy (excluding ACEI and ARB)
 - Onset hypertension ≤ 20 years or ≥ 50 years
 - Hypertension with abdominal or flank bruit
 - Moderate hypertension (DBP > 105-120 mmHg) in patients with evidence of occlusive vascular disease in the abdomen or the legs, and patients with a serum creatinine
3. A high index of clinical suspicion
 - Severe hypertension with either progressive renal insufficiency or refractoriness to standard treatment, especially in patients with evidence of occlusive vascular disease in the abdomen or legs
 - Accelerated or malignant hypertension
 - Hypertension with a recent elevation of serum creatinine induced by an ACEI (13)

Management and Therapy. RAS requires serious and immediate management because it has the potential to be cured by eliminating the underlying cause of renal artery stenosis. The goal of RAS therapy is to reduce morbidity and mortality due to increased blood pressure, prevent the progression of renal artery stenosis which can cause a decrease in kidney function, prevent cardiovascular target organ complications that are detrimental, and reduce the likelihood of recurrent pulmonary edema. Pharmacological therapy with antihypertensive drugs can control hypertension but does not affect the progression of the lesions. Therefore subsequent RAS management is carried out by revascularization.

Three therapeutic modalities can be chosen in the management of RAS; pharmacological therapy by administering antihypertensive drugs, revascularization with percutaneous intervention, and surgical intervention. These three therapeutic modalities are not independent but can be combined. Several factors must be considered in choosing which therapeutic approach to be used [14]. Each therapeutic modality has its advantages and disadvantages.

Pharmacological Therapy. Pharmacological therapy for renovascular hypertension does not differ considerably with essential hypertension. Sometimes, a combination of several types of antihypertensive drugs is needed to get optimal blood pressure control. By its pathophysiology, first-line therapy recommended are agents that inhibit the RAA system such as ACEI or ARB. If the blood pressure target has not been reached, Calcium Channel Blocker (CCB) or diuretic can be given. The recommended blood pressure target is below 140/90 mmHg or below 130 / 80mmHg for patients with chronic kidney failure (CKD) and diabetes. Special attention must be considered if we want to give an ACEI or ARB. Both of these drugs are options for uni-

lateral stenosis with functioning contralateral kidney. Conversely, the administration of ACEI or ARB is contraindicated in bilateral renal artery stenosis, unilateral stenosis with contralateral renal dysfunction, or a single kidney with renal artery stenosis because it can cause deterioration of renal function and acute renal failure. Acute kidney failure occurs because ACEI generates a loss of glomerular transcapillary filtration pressure as a result of the dilation of efferent arterioles through angiotensin II blockage [15].

Van de Ven et al. conducted a study on 108 hypertensive patients with a high risk of RAS. All patients received two weeks of ACEI therapy. There was an increase in serum creatinine more than 20% in 52 patients with severe bilateral RAS. However, this increase in serum creatinine is always reverted after the use of ACEI stop [16]. Therefore it can be concluded that increasing serum creatinine induced by ACEI is a very sensitive parameter to bilateral RAS in high-risk groups [17]. Long-term studies of more than 6-24 months investigation in small numbers of patients, show ACEI is an effective medication in reducing or normalizing blood pressure and does not lead to decreased kidney size and function [18].

CCB is a vasodilator that affects the afferent arterioles. CCB increases GFR and reduces serum creatinine. CCB does not change the excretion of microalbumin in the urine. In RAS patients, this drug does not decrease renal function like ACE inhibitors. Other pharmacological therapies are beta-blockers. Beta-blockers are also useful in reducing blood pressure because their work that inhibits renin secretion, but the risk of decreasing GFR in the stenotic kidney still occurs. Diuretics can be used in resistant hypertension but are generally not very effective.

Revascularization with Surgical Intervention. Various types of revascularization surgery techniques that can be done include unilateral nephrectomy, partial nephrectomy in segmental hypoplasia and stenosis in the branches of the renal artery, endarterectomy, in situ aortorenal bypass, alternative bypass, atherectomy, and extracorporeal microvascular reconstruction and autotransplantation for stenosis in the renal artery branches. The revascularization surgery technique chosen depends on the location, extent, and severity of the lesion in the renal artery. Some cases are recommended for immediate revascularization with surgery such as extensive cases to segmental arteries FMD with microaneurysms, multiple ARAS in the ventral branch, and ARAS which at the same time requires aortic reconstruction, for example in patients with aortic aneurysms or severe aortoiliac occlusion. For ostial atherosclerotic lesions, aortorenal endarterectomy and bypass aortorenal can be performed. Grafts for FMD lesions can be harvested from the hypogastric artery. Aortorenal vein bypass grafts can also be done for atherosclerotic lesions and fibromuscular lesions.

In the last decade, percutaneous intervention has begun to replace surgery. This is because the percuta-

neous modality provides a less invasive and more accessible to implement with same or more therapeutic benefits. Percutaneous angioplasty and stenting have become a standard approach in several countries. This is why surgical revascularization declines dramatically.

Revascularization with Percutaneous Intervention. Percutaneous intervention can be carried out as balloon angioplasty with or without stenting. Dotter and Judkins first introduced percutaneous Transluminal Renal Angioplasty (PTRA) in 1964 and was later developed and modified by Gruntzig et al. in 1978. Since the first introduced, PTRA received widespread attention. PTRA has advantages in the absence of general anesthesia and shorter hospital stays. There are many reports of the success of PTRA procedure, even some of them suggest PTRA as an initial RAS management [19].

PTRA Balloon Angioplasty. PTRA is the treatment of choice in FMD cases to reduce blood pressure and prevent the worsening of ischemic nephropathy. The success rate of this technique reaches 85-100%, where 55% of patients can be cured and 40% have improved significant blood pressure control. The incidence of recurrent stenosis after PTRA is also quite low (5-10%) in the first year after revascularization [20]. In ARAS, the success of PTRA is less than FMD. This is because stenosis due to atherosclerosis is more rigid lesions so the higher tendency of the arteries to return to their initial form (elastic recoil). The risk of arterial dissection is also high in ARAS [17].

PTRA with Stenting. The approach of PTRA followed with stenting started when failure rates and restenosis rates after PTRA procedure are high. The installation of a stent can ensure the stenosis part does not collapse after dilatation using balloon angioplasty. At first, stents used a simple stainless-steel coil, but in 1969, Dotter introduced metallic stents for intravascular use. Since then, there have been many various types of stents, both in terms of material and design.

Angioplasty with stenting is the recommended treatment option in ARAS cases. Several studies have shown that there is a significant reduction in blood pressure after stenting in ARAS patients [17]. However, renal dysfunction as a stenting adverse event has been found in several studies. The worsening kidney function is suspected because of atheroembolism. Atheroembolism happens because the stent that is placed tears the atheroma plaque so that microembolism is released. Microembolism clogs the microcirculation at the bottom of the stent and causes a significant decrease in kidney function after stenting. Renal dysfunction from embolism may manifest in several weeks to months after the installation of stents. Atheroembolism is often mistaken with kidney damage because of the contrast material used during the procedure. This adverse event can be prevented by installing an embolic protection device distal to the lesion. Embolic protection devices installed at the bottom of the lesion before stenting are expected to capture lost debris during the installation of stents so that they can help reduce the risk of athero-

embolism. Malposition, migration, embolization of the stents, and difficulties in pulling the balloon from stents are also limitations of this technique [18].

Pharmacology and Revascularization comparison therapy. Until now, the most superior therapeutic modalities in the management of renovascular hypertension caused by RAS are still under debate. There are several randomization studies that compare the effectiveness of therapy with revascularization and pharmacological therapy alone, including:

1. Essai Multicentrique Medicaments vs. Angioplastie (EMMA)
2. Scottish and Newcastle Renal Artery Stenosis Collaborative Group (SNRASCg)
3. Dutch Renal Artery Stenosis Intervention Cooperative (DRASTIC)
4. Angioplasty and Stenting for Renal Artery Lesions (ASTRAL)
5. The Benefit Stent Placement and Blood Pressure and Lipid-lowering for The Prevention of Progression of Renal Dysfunction Caused by Atherosclerotic Ostial Stenosis of The Renal Artery (STAR)
6. Nephropathy Ischemic Therapy (NITER)
7. A Randomized, Multicenter, Prospective Study Comparing Best Medical Treatment Versus Best Medical Treatment Plus Renal Artery Stenting in Patients with Hemodynamically Relevant Atherosclerotic Renal Artery Stenosis (RADAR)
8. Cardiovascular Outcomes in Renal Atherosclerotic Lesions (CORAL)

From the studies, there are two most extensive studies ASTRAL (2009) with 850 subjects and CORAL (2014) with 950 subjects. The ASTRAL study did not show any significant differences in blood pressure control between the two groups [15]. CORAL compares the results of stenting with pharmacological therapy in ARAS cases. In the group that received stent placement, a significant reduction in blood pressure was found, but this therapeutic modality did not reduce cardiovascular events [21].

From the meta-analysis of the eight studies, there were no significant differences in the increase of serum

creatinine and the incidence of cardiovascular also renal complications [22]. However, there are significant differences in increasing diastolic pressure and reducing the amount of antihypertensive medication in the stenting group compared to pharmacological therapy only. Overall, the results of the meta-analysis show that the benefits of revascularization for patients with RAS are still limited [22].

Prognosis. Renovascular hypertension is hypertension which has the potential to be cured by removing the underlying cause of RAS. The retrospective study reported that the mortality rate is 30% in 3 years and 35% in 5 years due to cardiovascular events and strokes. However, in patients with end-stage chronic kidney failure, the survival rate is decreased, 18% in 5 years and 5% in 10 years [7].

Conclusion. Renovascular hypertension is the most prevalent secondary hypertension. It is commonly caused by the presence of RAS. ARAS and FMD are the most common causes of RAS. Early diagnosis is necessary because this disorder has the potential to be cured by eliminating renal artery stenosis. Renovascular hypertension has non-specific signs and symptoms, so screening the populations at risk is recommended. The gold standard examination is to prove the presence of RAS is by arteriographic examination. Other newer examination modalities include captopril renogram, USG renal, USG Doppler, MRA, and CTA. Until now, three therapeutic modalities can be selected in the management of renovascular hypertension; pharmacological therapy through the administration of antihypertensive drugs, surgical intervention, revascularization with angioplasty with and without stenting. The renovascular hypertension prognosis is quite good, except in patients with end-stage chronic kidney failure.

Conflict of interest. The authors declare no conflict of interest.

Financial support and sponsorship. None

Contribution. IPD conceived idea and write the review manuscript. KPD help gathered the evidenced. NM is senior supervisor that contributed in writing the manuscript. All authors read and approved the final manuscript.

References:

1. *Moraes F De, Lacerda MB, Moreno LA.* Prevalence of High Blood Pressure in 122 ,053 Adolescents: A Systematic Review and Meta-Regression. *Medicine (Baltimore).* 2014;93(27):1–10. doi: 10.5546/aap.2017.eng.5
2. *Berl T, Himmelfarb J, Mitch WE, Murphy B, Salant DJ, Yu AS.* Therapy in Nephrology & Hypertension. 2008. isbn: 9780323249454
3. *Falah A, Harun H.* Hipertensi Renovaskular. *J Kesehat Andalas.* 2018;7:70–3. doi: <https://doi.org/10.25077/jka.v7i0.852>
4. *Chonchol M, Linas S.* Diagnosis and Management of Ischemic Nephropathy. *Clin J Am Soc Nephrol.* 2006;1:172–81. doi: <https://doi.org/10.2215/CJN.00940905>
5. *Weber BR, Dieter RS.* Renal artery stenosis : epidemiology and treatment. *Int J Nephrol dan Renov Dis.* 2014;7:169–81. doi: 10.2147/IJNRD.S40175. eCollection 2014
6. *Lao D, Parasher PS, Cho KC, Yeghiazarians Y.* Atherosclerotic Renal Artery Stenosis – Diagnosis and Treatment. *Mayo Clin Proc.* 2011;86(7):649–57. doi: 10.4065/mcp.2011.0181

7. *Textor SC, Greco BA.* Renovascular Hypertension and Ischemic Renal Disease. Fourth Edi. Comprehensive Clinical Nephrology. Elsevier Inc.; 2010. 451–468 p. doi: <http://dx.doi.org/10.1016/B978-0-323-05876-6.00037-X>
8. *Bavishi C, Leeuw PW De, Messerli FH.* Atherosclerotic Renal Artery Stenosis and Hypertension: Pragmatism, Pitfalls, and Perspectives. *Am J Med.* 2016;129(6):635.e5-635.e14. doi: <http://dx.doi.org/10.1016/j.amjmed.2015.10.010>
9. *Holley K, Hunt J, Brown A, Kincaid O, Sheps S.* Renal Artery Stenosis A Clinical – Pathologic Study in Normotensive and Hypertensive Patients. *Am J Med.* 1964;37:14–22
10. *Mann SJ, Pickering TG, Sos TA, Uzzo RG, Sarkar S, Friend K, et al.* Captopril Renography in the Diagnosis of Renal Artery Stenosis: Accuracy and Limitations. *Am J Med.* 1991;90:30–40. doi: [https://doi.org/10.1016/0002-9343\(91\)90503-P](https://doi.org/10.1016/0002-9343(91)90503-P)
11. *Zierler R, Bergelin R, Davidson R, Cantwell-Gab K, Polissar N, Strandness DJ.* A prospective study of disease progression in patients with atherosclerotic renal artery stenosis. *Am J Hypertens.* 1996;(11):1055–61. doi: [https://doi.org/10.1016/0895-7061\(96\)00196-3](https://doi.org/10.1016/0895-7061(96)00196-3)
12. *Schaberle W, Leyerer L, Schierling W, Pfister K.* Ultrasound diagnostics of renal artery stenosis. *Gefässchirurgie.* 2016;21:S4–13. doi: [10.1007/s00772-015-0060-3](https://doi.org/10.1007/s00772-015-0060-3)
13. *Mann SJ, Pickering TG.* Detection of Renovascular Hypertension: State of Art. *Ann Intern Med.* 1992;117:845–53. doi: [10.7326/0003-4819-117-10-845](https://doi.org/10.7326/0003-4819-117-10-845)
14. *Martin LG, Rundback JH, Wallace MJ, Cardella JF, Angle JF, Kundu S et al.* Quality Improvement Guidelines for Angiography, Angioplasty, and Stent Placement for the Diagnosis and Treatment of Renal Artery Stenosis in Adults. *J Vasc Interv Radiol.* 2010;21:421–30. doi: <http://dx.doi.org/10.1016/j.jvir.2009.12.391>
15. *Wheatley K, Ives N, Gray R, Philip A, Hos- SR, Moss JG, et al, The ASTRAL Investigators.* Revascularization versus Medical Therapy for Renal-Artery Stenosis. *N Engl J Med.* 2009;361:1953–62. doi: [10.1056/NEJMoa0905368](https://doi.org/10.1056/NEJMoa0905368)
16. *van de Ven PJG, Kaatee R, Beutler JJ, Beek FJA, Woittiez AJ, Buskens E, et al.* Early reports Arterial stenting and balloon angioplasty in ostial atherosclerotic renovascular disease: a randomised trial. *Lancet.* 1999;353:282–6. doi: [10.1016/S0140-6736\(98\)04432-8](https://doi.org/10.1016/S0140-6736(98)04432-8)
17. *Bax L, Woittiez AJ, Kouwenberg HJ, Buskens E.* Annals of Internal Medicine Stent Placement in Patients With Atherosclerotic Renal Artery Stenosis and Impaired Renal Function: A Randomized Trial. *Ann Intern Med.* 2009;150:840–8. doi: [10.7326/0003-4819-150-12-200906160-00119](https://doi.org/10.7326/0003-4819-150-12-200906160-00119)
18. *Jaff MR, Bates M, Sullivan T, Popma J, Gao X, Zaugg M, et al.* Significant Reduction in Systolic Blood Pressure Following Renal Artery Stenting in Patients With Uncontrolled Hypertension: Results From The HERCULES Trial. *Catheter an Cardiovasc Interv.* 2012;000:000–000. doi: <https://doi.org/10.1002/ccd.24449>
19. *Hu Y, Zhang Y, Wang H, Yin Y, Cao C, Luo J, et al.* Percutaneous renal artery stent implantation in the treatment of atherosclerotic renal artery stenosis. *Experimetal Ther Med.* 2018;16:2331–6. doi: [10.3892/etm.2018.6440](https://doi.org/10.3892/etm.2018.6440)
20. *Trinquart L, Mounier-vehier C, Sapoval M, Gagnon N.* Efficacy of Revascularization For Renal Artery Stenosis Caused by Fibromuscular Dysplasia A Systematic Review and Meta-Analysis. *Hypertension.* 2010;56:525–32. doi: <https://doi.org/10.1161/HYPERTENSIONAHA.110.152918>
21. *Cooper CJ, Murphy, Timothy P Cutlip DE, Jamerson K, Henrich W, Reid DM, Cohen, David J Matsumoto AH, et al.* Stenting and Medical Therapy for Atherosclerotic Renal-Artery Stenosis Christopher. *N Engl J Med.* 2014;370(1):13–22. doi: [10.1056/NEJMoa1310753](https://doi.org/10.1056/NEJMoa1310753)
22. *Jenks S, Yeoh S, Conway B.* Balloon angioplasty, with and without stenting, versus medical therapy for hypertensive patients with renal artery stenosis (Review). *Cochrane Collab John Wiley Sons, Ltd.* 2014;(12). doi: [10.1002/14651858.CD002944.pub2](https://doi.org/10.1002/14651858.CD002944.pub2)