




## REPORTS OF MORPHOLOGY

Official Journal of the Scientific Society of Anatomists,  
Histologists, Embryologists and Topographic Anatomists  
of Ukraine

journal homepage: <https://morphology-journal.com>



### Features of total and longitudinal body sizes in men with benign nevi

Nabil Basim Yousif Haddad, Serebrennikova O.A., Gunas I.V., Kyrychenko Yu.V., Rekun T.O.

National Pirogov Memorial Medical University, Vinnytsya, Ukraine

#### ARTICLE INFO

Received: 26 July 2021

Accepted: 27 August 2021

UDC: 616.5-003.829-037-084-07

#### CORRESPONDING AUTHOR

e-mail: [nabil.basim@gmail.com](mailto:nabil.basim@gmail.com)

Nabil Basim Yousif Haddad

*The use of anthropometric markers to predict the onset or severity of the disease is key to solving the problem of preventive medicine and can be an indispensable tool in preventive examinations in schools, universities and industries. The purpose of the study was to establish total and longitudinal body sizes in men of the first mature age with benign nevi. Anthropometry (determination of total and longitudinal body sizes) was performed according to Bunak's scheme for men (aged 22-35 years) patients with melanocytic benign simple nevi (n=34), melanocytic benign dysplastic nevi (n=27), melanocytic benign congenital nevi (n=14) and non-melanocytic benign nevi (n=17). As a control from the data bank of the research center of National Pirogov Memorial Medical University, Vinnytsya selected total and longitudinal body sizes of 82 practically healthy men of the same age group. Statistical processing of the obtained results was performed in the license package "Statistica 5.5" using non-parametric evaluation methods. It was found that the mass and surface area of the body in healthy men is lower than in patients (except for dysplastic nevi), and in patients with dysplastic nevi - lower than in patients with non-melanocytic nevi; the height of the suprathoracic, acromial and finger anthropometric points in healthy men is lower than in patients with nevi (except for the height acromial point in patients with dysplastic nevi), and the height of the pubic and acetabular anthropometric points - in healthy men is greater than in patients with simple (only pubic point) and dysplastic nevi; in addition, the height of the pubic and acetabular anthropometric points in patients with simple nevi is lower than in patients with non-melanocytic nevi and congenital nevi (only for the acetabulum height). Given the height of anthropometric points and the fact that body length between healthy and sick men has no significant or tendency differences, in sick men we observe a longer torso and shorter lower extremities (most pronounced in patients with simple and dysplastic nevi), which is a manifestation of "subpathological" constitutional types, which indicate a longer torso and shorter lower extremities.*

**Keywords:** benign nevi, total body sizes, longitudinal body sizes, men.

#### Introduction

Perhaps the most urgent task of medicine of this century is to prevent the disease by modifying the patient's life, or if this is not possible, to alleviate the severity of the disease. However, achieving this goal from a practical point of view is currently practically impossible due not only to the high cost of the study and the requirements for the availability of modern DNA laboratory. Moreover, there can be no question of using this method as a screening among the general population.

That is why clinical anthropology is becoming more widespread, which allows to predict the risks of certain diseases [5], the severity of their course, features of psychoneurological status [3], ethnic and regional affiliation of the person [11] and so on.

In this case, anthropometry is a simple method of examination that does not require long and complex training, material resources or highly developed laboratory and instrumental facilities. Instead, physicians have the opportunity to apply the scientific advances of clinical anthropology in the examination of large masses of the population, in particular, during preventive examinations, which in the future, after processing the information obtained, will create risk groups.

One of the areas of medicine that needs such a powerful preventive tool is oncodermatology, which studies both benign and malignant skin tumors. Benign melanocytic nevi in this group of diseases occupy an important place. Their prevalence is quite heterogeneous and varies from

0.5% to 31.7% of the population in different countries; in newborns, nevi are found in one of 20,000-500,000 births; the ratio of men and women with benign nevi is about 3:2; transformation of benign nevi into melanoma occurs according to some authors in 19-21% of cases, although most authors tend to 1% [1].

In the field of external genitalia in women, the frequency of detection of nevi is 2%, which in turn is 23% of all pigmented tumors in this area. Researchers have also noted frequent cases of malignancy of these nevi with the formation of melanoma [17].

The anthropometric method has proven itself well in research on different types of cancer and their different localizations, in particular, successful data have been obtained on cancer of the head and neck, stomach, colon, pancreas, esophagus, lungs, liver, bladder, kidneys, uterus [5, 9].

Given the possibility of malignancy of such benign skin neoplasms as melanocytic nevi, and the successful experience of foreign researchers to study anthropometric indicators in various cancers, there is a need to study the features of these indicators in people with benign nevi.

The purpose of the study was to establish total and longitudinal body sizes in men of the first mature age with benign nevi.

**Materials and methods**

Men of the first mature age (22-35 years) with melanocytic benign simple nevi (n=34), melanocytic benign dysplastic nevi (n=27), melanocytic benign congenital nevi (n=14) and melanocytic benign nevi (n=17), who underwent clinical-laboratory and pathohistological examinations on the basis of the Military Medical Clinical Center of the Central Region and the Department of Skin and Venereal Diseases with a course of postgraduate education of National Pirogov Memorial Medical University, Vinnytsya, anthropometry was performed according to the scheme of V.V.Bunak [7].

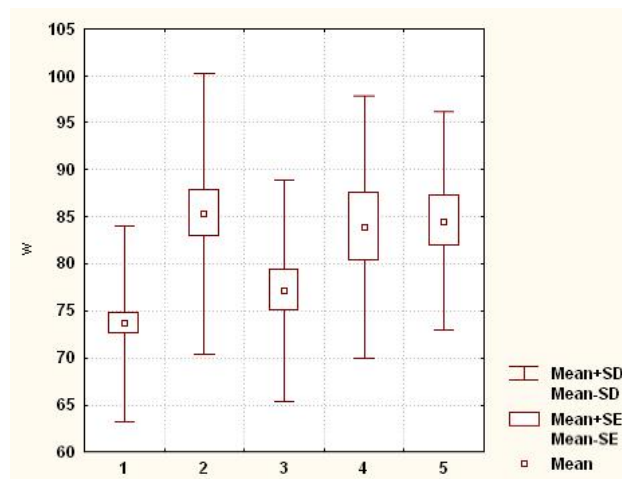
Diagnosis of nevi was performed according to a two-stage algorithm for the classification of pigmented tumors, which was adopted at the First World Congress of Dermatoscopy (Rome, 2001) [18].

As a control from the database of the research center of the National Pirogov Memorial Medical University, Vinnytsya were selected total and longitudinal body sizes of 82 practically healthy men of the same age group.

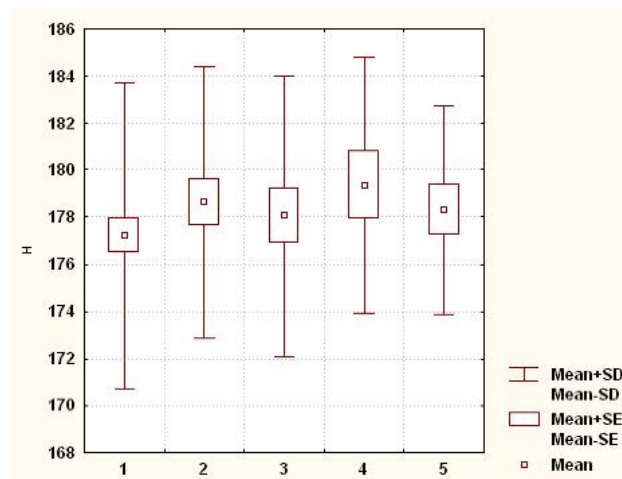
Statistical processing of the obtained results was performed in the license package "Statistica 5.5" using non-parametric evaluation methods. The reliability of the difference between the values between the independent quantitative values was determined using the Mann-Whitney U-test.

**Results**

It was found that body weight in healthy men is significantly (p<0.05-0.001) lower than in men with



**Fig. 1.** Body weight (W) in healthy and sick men with melanocytic nevi (kg). In this and the following figures: 1 - healthy men; 2 - men with melanocytic benign simple nevi; 3 - men with melanocytic benign dysplastic nevi; 4 - men with melanocytic benign congenital nevi; 5 - men with non-melanocytic benign nevi; Mean - average value; Mean ± SE - average value ± mean error; Mean±SD - mean ± standard deviation.



**Fig. 2.** Body length (H) in healthy and sick men with melanocytic nevi (cm).

melanocytic benign simple and congenital nevi and non-melanocytic benign nevi, and in men with melanocytic benign dysplastic nevi - significantly lower (p<0.05) and tends (p=0.054) to lower values than in patients with melanocytic benign simple and non-melanocytic benign nevi (Fig. 1).

There are no reliable or tendencies of differences between healthy and sick, or between men with benign nevi (Fig. 2).

Body surface area, as well as body weight, in healthy men is significantly (p<0.05-0.001) lower than in men with melanocytic benign simple and congenital nevi and non-melanocytic benign nevi, and in men with melanocytic benign dysplastic nevi - significantly smaller (p<0.05) and tends (p=0.075) to lower values than in patients with

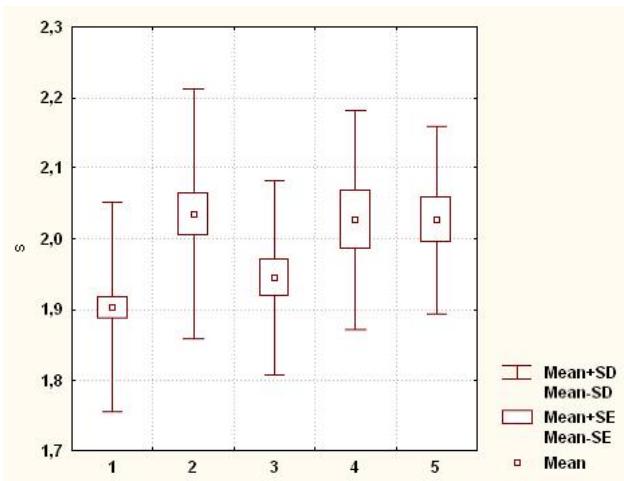


Fig. 3. Body surface area (S) in healthy and sick men with melanocytic nevi (m<sup>2</sup>).

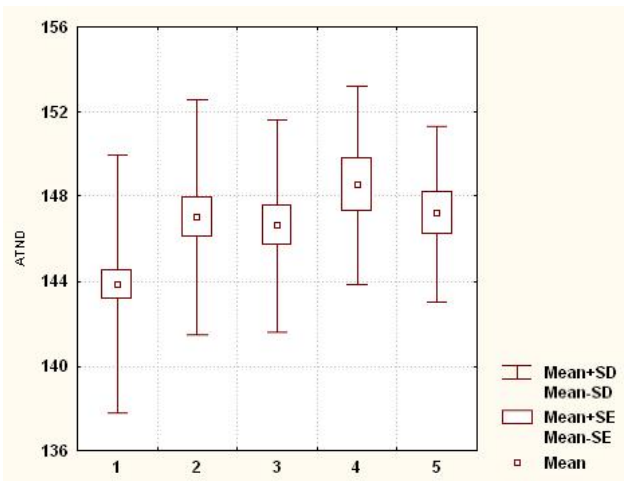


Fig. 4. Height of the suprathoracic anthropometric point (ATND) in healthy and sick men with melanocytic nevi (cm).

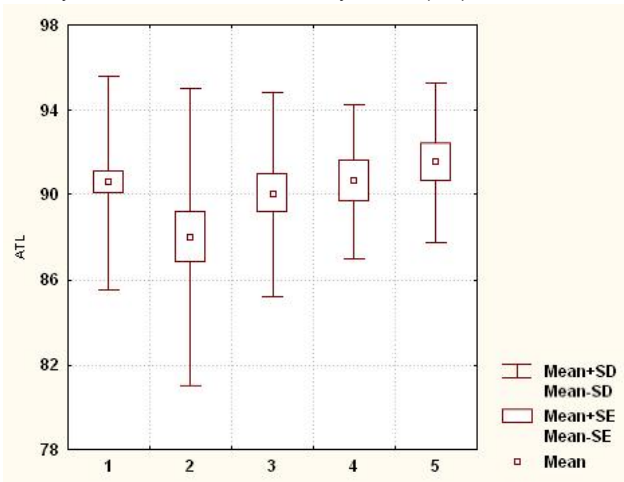


Fig. 5. Height of the pubic anthropometric point (ATL) in healthy and sick men with melanocytic nevi (cm).

melanocytic benign simple and non-melanocytic benign nevi (Fig. 3).

The height of the suprachoroidal anthropometric point in healthy men is significantly ( $p < 0.05-0.01$ ) lower than in men with melanocytic benign simple, dysplastic and congenital nevi and non-melanocytic benign nevi (Fig. 4).

The height of the pubic anthropometric point in patients with melanocytic benign simple nevi of men is significantly ( $p < 0.05$ ) lower than in healthy and patients with non-melanocytic benign nevi of men (Fig. 5).

The height of the acromial anthropometric point in healthy men is significantly ( $p < 0.05$ ) lower and tends ( $p = 0.064$ ) to lower values than in men with melanocytic benign simple and congenital nevi and non-melanocytic benign nevi (Fig. 6).

The height of the finger anthropometric point in healthy men is significantly ( $p < 0.05-0.001$ ) lower than in men with melanocytic benign simple, dysplastic and congenital nevi and non-melanocytic benign nevi (Fig. 7).

The height of the acetabular anthropometric point in healthy men is significantly ( $p < 0.01-0.001$ ) greater than in

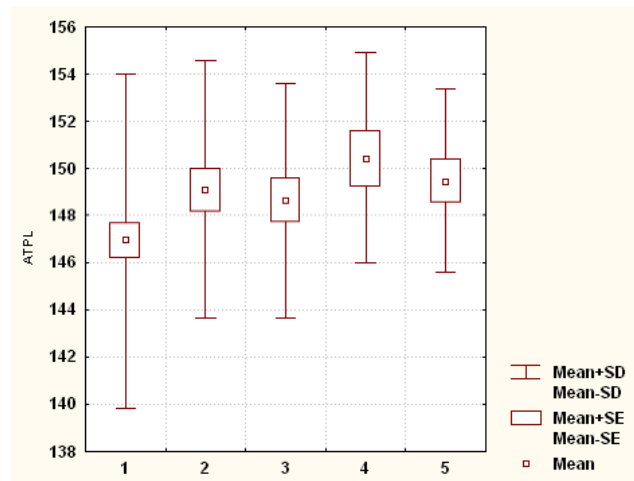


Fig. 6. Height of acromial anthropometric point (ATPL) in healthy and sick men with melanocytic nevi (cm).

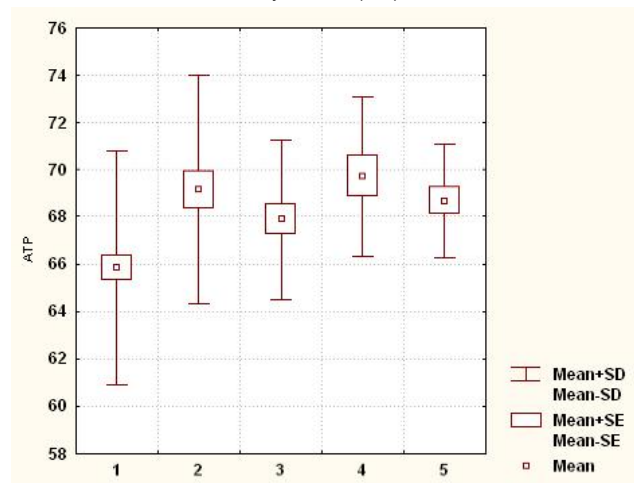
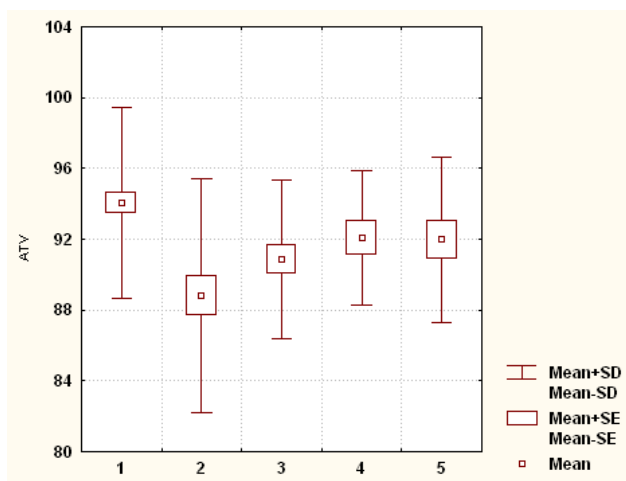


Fig. 7. Height of the finger anthropometric point (ATP) in healthy and sick men with melanocytic nevi (cm).



**Fig. 8.** Height of the acetabular anthropometric point (ATV) in healthy and sick men with melanocytic nevi (cm).

men with melanocytic benign simple and dysplastic nevi, and in men with melanocyte benign simple nevi - significantly lower ( $p < 0.05$ ) than in patients with melanocytic benign congenital and non-melanocytic benign nevi (Fig. 8).

**Discussion**

In the analysis of total and longitudinal body size between healthy and patients with benign nevi men found (Table 1): body weight and surface area in healthy men is significantly smaller than in patients (except for melanocyte benign dysplastic nevi); the height of the suprathoracic, acromial and finger anthropometric points in healthy men is significantly less or tends to lower values than in patients with nevi (except for the acromial point in men with melanocyte benign dysplastic nevi), and the height of the

**Table 1.** Differences in total and longitudinal body size between healthy and sick with benign nevi, as well as between sick men.

Indicators	Healthy	Sick			
		MSN	MDN	MCN	NM
Body weight	N	D	-	D	D-
Body surface area	N	D	-	D	D-
Body length					
Height of the suprathoracic point	N	D	D	D	D
Pubic point height	D	N	N		N
The height of the acromial point	N-	-		D	D
The height of the finger point	N	D	D	D	D
The height of the acetabular point	D	N	N	D	D

**Notes:** MSN - melanocytic benign simple nevi; MDN - melanocytic benign dysplastic nevi; MCN - melanocytic benign congenital nevi; NM - non-melanocytic benign nevi; **D** or **N** - significant differences between healthy and sick men; **-** or **-** - trends in differences between healthy and sick men; **D** or **N** - significant differences in performance between sick men; **-** or **-** - tendencies of differences of indicators between sick men.

pubic and acetabular men are significantly larger than in patients with melanocyte benign simple (pubic point only) and dysplastic nevi. Given the height of anthropometric points and the fact that body length between healthy and sick men has no significant or tendency to differ, in sick men we observe a longer torso and shorter lower extremities (most pronounced in patients with melanocytic benign simple and dysplastic nevi).

In the analysis of total and longitudinal body sizes between men with benign nevi, it was found (see Table 1): body weight and surface area in patients with melanocytic benign dysplastic nevi tend to be lower than in patients with non-melanocytic benign nevi; the height of the pubic and acetabular anthropometric points in patients with melanocytic benign simple nevi is significantly lower than in patients with non-melanocytic benign nevi and melanocytic benign congenital nevi (only for the acetabulum point).

Foreign authors have obtained convincing research results that confirm the relationship between anthropometric indicators and a particular cancer type. Mexican researchers have found that height, BMI, waist, thighs circumferences and their ratio are associated with the risk of breast cancer (from  $p < 0.001$  to  $p < 0.016$ ) [2]. Similar data on the relationship of anthropometric parameters with the risk of breast cancer have been found in other works [12, 21].

In addition, an association was found between waist circumference and BMI and the risk of ovarian cancer [4], BMI, WHR and the risk of prostate cancer [6], BMI, WHR in different age categories and the risk of pancreatic cancer [10], BMI, hip circumference and abdominal circumference in both men and women and the risk of colorectal cancer [13, 22], waist and hip circumference, BMI in non-smokers and the risk of lung cancer [15], BMI, weight, hip circumference, waist circumference, WHR and the ratio of waist circumference to the growth and risk of bladder cancer [19] and BMI, WHR and the risk of thyroid cancer [20].

At the same time, studies on about anthropometric parameters in people with benign or malignant skin tumors are quite small in number, and most of the work presented in scientometric databases relate to patients with melanoma.

A long-term survey of 71,645 postmenopausal women found that 18.6% of them developed skin cancer over time. An anthropometric examination found that a body mass index (BMI)  $\geq 25$  kg/m<sup>2</sup> or a waist-to-thigh ratio (WHR)  $\geq 0.80$  was associated with a lower risk of skin cancer [8].

M. Kvaskoff and co-authors [14] established a relationship between the risk of melanoma of the skin and age (RR = 1.27, 95% CI=1.05-1.55 for  $\geq 164$  cm vs.  $< 164$  cm;  $p = 0.02$ ). These data were confirmed by K.D.Meyle and others [16]. They found an association between growth at age 13 and the risk of melanoma in adulthood.

Thus, the data obtained as a result of our study not only agree with the data of other foreign studies but also

complement the few theoretical data of clinical anthropology related to the study of oncodermatology.

## Conclusions

1. Numerous differences of total and longitudinal body sizes have been established between healthy and sick men with benign nevi, which reflect the manifestations of

"subpathological" constitutional types in patients, namely, a longer torso and shorter lower extremities.

2. Differences between men with different benign nevi mainly concern the shorter lower extremities in men with melanocytic benign simple nevi compared to non-melanocytic and melanocytic congenital nevi.

## References

- [1] Alikhan, A., Ibrahim, O.A., & Eisen, D.B. (2012). Congenital melanocytic nevi: where are we now?: part I. Clinical presentation, epidemiology, pathogenesis, histology, malignant transformation, and neurocutaneous melanosis. *Journal of the American Academy of Dermatology*, 67(4), 495.e1-495.e17. doi: 10.1016/j.jaad.2012.06.023
- [2] Amadou, A., Mejia, G.T., Fagherazzi, G., Ortega, C., Angeles-Llerenas, A., Chajes, V. ... Romieu, I. (2014). Anthropometry, silhouette trajectory, and risk of breast cancer in Mexican women. *American Journal of Preventive Medicine*, 46(3), S52-S64. doi: 10.1016/j.amepre.2013.10.024
- [3] Andriievskiy, I.I., Serebrennikova, O.A., Kyrychenko, I.M., Zhuchenko, I.I., & Gunas, V.I. (2020). Correlations of body structure and size indicators with personality indicators of practically healthy women with mesomorphic somatotype. *Biomedical and Biosocial Anthropology*, (39), 35-44. doi: 10.31393/bba39-2020-06
- [4] Aune, D., Navarro Rosenblatt, D.A., Chan, D.S.M., Abar, L., Vingeliene, S., Vieira, A.R. ... Norat, T. (2015). Anthropometric factors and ovarian cancer risk: A systematic review and nonlinear dose-response meta-analysis of prospective studies. *International Journal of Cancer*, 136(8), 1888-1898. doi: 10.1002/ijc.29207
- [5] Bandera, E.V., Fay, S.H., Giovannucci, E., Leitzmann, M.F., Marklew, R., McTiernan, A. ... World Cancer Research Fund International Continuous Update Project Panel. (2016). The use and interpretation of anthropometric measures in cancer epidemiology: A perspective from the world cancer research fund international continuous update project. *International Journal of Cancer*, 139(11), 2391-2397. doi: 10.1002/ijc.30248
- [6] Boehm, K., Sun, M., Larcher, A., Blanc-Lapierre, A., Schiffmann, J., Graefen, M. ... Karakiewicz, P.I. (2015). Waist circumference, waist-hip ratio, body mass index, and prostate cancer risk: results from the North-American case-control study Prostate Cancer & Environment Study. *In Urologic Oncology: Seminars and Original Investigations*, 33(11), 494-e1. doi: 10.1016/j.urolonc.2015.07.006
- [7] Bunak, V.V. (1941). *Антропометрия [Anthropometry]*. М.: Наркомпрос РСФСР - М.: People's Commissariat of the RSFSR.
- [8] Chan, A.A., Noguti, J., Pak, Y., Qi, L., Caan, B., Going, S. ... Lee, D.J. (2019). Interaction of body mass index or waist to hip ratio and sun exposure associated with nonmelanoma skin cancer: A prospective study from the Women's Health Initiative. *Cancer*, 125(7), 1133-1142. doi: 10.1002/cncr.31810
- [9] Christakoudi, S., Tsilidis, K.K., Evangelou, E., & Riboli, E. (2021). A Body Shape Index (ABSI), hip index, and risk of cancer in the UK Biobank cohort. *Cancer Medicine*, 10(16), 5614-5628. doi: 10.1002/cam4.4097
- [10] Genkinger, J.M., Spiegelman, D., Anderson, K.E., Bernstein, L., Van Den Brandt, P.A., Calle, E.E. ... Warner, S.A. (2011). A pooled analysis of 14 cohort studies of anthropometric factors and pancreatic cancer risk. *International Journal of Cancer*, 129(7), 1708-1717. doi: 10.1002/ijc.25794
- [11] Gunas, V.I., Mishalov, V.D., Serebrennikova, O.A., Klimas, L.A., & Shayuk, A.V. (2018). Palmar dermatoglyphics of modern Ukrainians: regional trends. *Biomedical and Biosocial Anthropology*, (31), 11-17. doi: 10.31393/bba31-2018-02
- [12] His, M., Biessy, C., Torres-Mejia, G., Angeles-Llerenas, A., Alvarado-Cabrero, I., Sánchez, G.I. ... Rinaldi, S. (2020). Anthropometry, body shape in early-life and risk of premenopausal breast cancer among Latin American women: results from the PRECAMA study. *Scientific Reports*, 10(1), 1-12. doi: 10.1038/s41598-020-59056-6
- [13] Keimling, M., Renehan, A.G., Behrens, G., Fischer, B., Hollenbeck, A.R., Cross, A.J., & Leitzmann, M.F. (2013). Comparison of associations of body mass index, abdominal adiposity, and risk of colorectal cancer in a large prospective cohort study. *Cancer Epidemiology and Prevention Biomarkers*, 22(8), 1383-1394. doi: 10.1158/1055-9965.EPI-13-0353
- [14] Kvaskoff, M., Bijon, A., Mesrine, S., Vilier, A., Clavel-Chapelon, F., & Boutron-Ruault, M.C. (2014). Anthropometric features and cutaneous melanoma risk: a prospective cohort study in French women. *Cancer Epidemiology*, 38(4), 357-363. doi: 10.1016/j.canep.2014.05.008
- [15] Lam, T.K., Moore, S.C., Brinton, L.A., Smith, L., Hollenbeck, A.R., Gierach, G.L., & Freedman, N.D. (2013). Anthropometric measures and physical activity and the risk of lung cancer in never-smokers: a prospective cohort study. *PLoS One*, 8(8), e70672. doi: 10.1371/journal.pone.0070672
- [16] Meyle, K.D., Gamborg, M., Hölmich, L.R., & Baker, J.L. (2016). Childhood body size and the future risk of morphologically different variants of malignant melanoma. *In European Obesity Summit (EOS) - Joint Congress of EASO and IFSO-EC*, 9(1), 60.
- [17] Murzaku, E.C., Penn, L.A., Hale, C.S., Pomeranz, M.K., & Polsky, D. (2014). Vulvar nevi, melanosis, and melanoma: an epidemiologic, clinical, and histopathologic review. *Journal of the American Academy of Dermatology*, 71(6), 1241-1249. doi: 10.1016/j.jaad.2014.08.019
- [18] Potekayev, N.N., Shuginina, Y.K., Kuzmina, T.S., & Arutyunyan, L.S. (2011). *Дерматоскопия в клинической практике. Руководство для врачей [Dermatoscopy in Clinical Practice. A Guide for Doctors]*. М: МДВ, 144 - М: MDV, 144.
- [19] Roswall, N., Freisling, H., Bueno-de-Mesquita, H.B., Ros, M., Christensen, J., Overvad, K. ... Halkjaer, J. (2014). Anthropometric measures and bladder cancer risk: a prospective study in the EPIC cohort. *International Journal of Cancer*, 135(12), 2918-2929. doi: 10.1002/ijc.28936
- [20] Schmid, D., Ricci, C., Behrens, G., & Leitzmann, M.F. (2015). Adiposity and risk of thyroid cancer: a systematic review and meta-analysis. *Obesity Reviews*, 16(12), 1042-1054. doi: 10.1111/obr.12321
- [21] Sexton, K.R., Franzini, L., Day, R.S., Brewster, A., Vernon, S.W., & Bondy, M.L. (2011). A review of body size and breast cancer risk in Hispanic and African American women. *Cancer*,

117(23), 5271-5281. doi: 10.1002/cncr.26217  
[22] Wang, N., Khankari, N.K., Cai, H., Li, H.L., Yang, G., Gao, Y.T.  
... Zheng, W. (2017). Prediagnosis body mass index and waist-

hip circumference ratio in association with colorectal cancer survival. *International Journal of Cancer*, 140(2), 292-301. doi: 10.1002/ijc.30459

#### **ОСОБЛИВОСТІ ТОТАЛЬНИХ І ПОЗДОВЖНИХ РОЗМІРІВ ТІЛА У ЧОЛОВІКІВ З ДОБРОЯКІСНИМИ НЕВУСАМИ**

**Набіль Басім Юсіф Хаддад, Серебреннікова О.А., Гунас І.В., Кириченко Ю.В., Рекун Т.О.**

Використання антропометричних маркерів для прогнозування виникнення чи тяжкості перебігу захворювання є ключем до розв'язання проблеми профілактичної медицини і може стати незамінним інструментом під час проведення профілактичних оглядів в школах, університетах та на виробництвах. Мета дослідження - встановити особливості тотальних і поздовжніх розмірів тіла у чоловіків першого зрілого віку, хворих на доброякісні невуси. Проведено антропометрію (визначення тотальних і поздовжніх розмірів тіла) за схемою Бунака чоловікам (віком 22-35 років), хворим на меланоцитарні доброякісні прості невуси (n=34), меланоцитарні доброякісні диспластичні невуси (n=27), меланоцитарні доброякісні вроджені невуси (n=14) та немеланоцитарні доброякісні невуси (n=17). В якості контролю з банку даних науково-дослідного центру Вінницького національного медичного університету ім. М.І.Пирогова були відібрані тотальні та поздовжні розміри тіла 82 практично здорових чоловіків аналогічної вікової групи. Статистичну обробку отриманих результатів проведено в ліцензійному пакеті "Statistica 5.5" з використанням непараметричних методів оцінки. Встановлено, що маса та площа поверхні тіла у здорових чоловіків менші, ніж у хворих (за винятком диспластичних невусів), а у хворих на диспластичні невуси - менша, ніж у хворих на немеланоцитарні невуси; висота надерудинної, акроміальної та пальцевої антропометричних точок у здорових чоловіків менша, ніж у хворих на невуси (за винятком висоти акроміальної точки у хворих на диспластичні невуси), а висота лобкової та вертлюгової антропометричних точок - у здорових чоловіків більша, ніж у хворих на прості (лише лобкової точки) та диспластичні невуси; крім того, висота лобкової та вертлюгової антропометричних точок у хворих на прості невуси менша, ніж у хворих на немеланоцитарні невуси та вроджені невуси (лише для висоти вертлюгової точки). Враховуючи висоту антропометричних точок і те, що довжина тіла між здоровими та хворими на невуси чоловіками не має достовірних або тенденцій розбіжностей, у хворих чоловіків ми спостерігаємо більш довгий тулуб і більш короткі нижні кінцівки (найбільш виражено у хворих на прості та диспластичні невуси), що є проявом "субпатологічних" конституціональних типів, які вказують на більш довгий тулуб і більш короткі нижні кінцівки.

**Ключові слова:** доброякісні невуси, тотальні розміри тіла, поздовжні розміри тіла, чоловіки.

---