

HISTOLOGICAL CHANGES IN THE RAT'S JEJUNUM WALL UNDER THE CONDITIONS OF ACTION OF COMMON EUROPEAN ADDER (*VIPERA BERUS BERUS*) VENOM

O. Maievskiy¹, I. Slieptsova²

¹ ННЦ «Інститут біології та медицини» Київського національного університету імені Тараса Шевченка (м. Київ, Україна)
e-mail: maievskiyalex8@gmail.com; ORCID: 0000-0002-9128-1033

² Інститут агроекології і природокористування НААН (м. Київ, Україна)
e-mail: inna7slyeptsova@gmail.com; ORCID: 0000-0001-6838-7924

Численні компоненти отруту різноманітних видів тварин викликають в організмі реципієнтів надзвичайно широкий спектр ефектів та симптомів. При цьому ступінь вираженості патологічних змін визначається, загалом, видом тварин, об'ємом та способом введення токсину, а також характерними особливостями жертви. Зміни структурно-функціональних параметрів стінки порожньої кишки на тлі впливу отрути гадюки звичайної все ще є недостатньо вивченими. Вкрай актуальними слід вважати дослідження, які направлені на виявлення нових компонентів змінних токсинів, визначення ступеня їх впливу на уражений організм та використання отриманих даних для виробництва антидотів, і тим самим, усунення економічних втрат, пов'язаних з укусами змій. Метою дослідження є встановлення проявів пошкодження тонкої кишки за умов дії отрути гадюки звичайної (*Vipera berus berus*). Експеримент проведено на 20 нелінійних білих щурах самцях. При дослідженні щурів розподіляли на дві групи — контрольну та дослідну. Отруєння моделювали введенням щурам дослідної групи внутрішньочеревно отрути гадюки звичайної в дозі ED₅₀ 1,576 мкг/г. Гістологічні препарати досліджували під світловим мікроскопом SEO SCAN, знімки опрацьовували за допомогою Vision CCD Camera з наявною системою виведення зображення на монітор комп'ютера. Було встановлено, що за умов дії отрути гадюки звичайної токсичні речовини її отрути викликають в стінці порожньої кишки деструктивно-дегенеративні зміни в рельєфі та стромально-судинному компонентах слизової оболонки органу. Таким чином, підвищення проникності стінок судин мікроциркуляторного русла, витончення і повна руйнація стінок гемокапілярів разом із цитотоксичною дією отрути на еритроцити призводить до утворення множинних, дрібних крововиливів з гемолізом еритроцитів.

Ключові слова: гадюки, тонкий кишечник, токсини, структурні зміни, отрута.

INTRODUCTION

Numerous components of venoms of various animal species cause an extremely wide range of effects and symptoms in the recipient's body. It is interesting to establish the interaction of the body with toxins and endogenous toxin-like molecules. The degree of severity of pathological changes in the body is determined, in general, by the type of animal, the volume and method of toxin administration, as well as the characteristic features of the victim [1–3]. Among numerous poisonous animals, it is vipers that have attracted the attention of scientists for several decades.

Such interest is caused by the features of the components of their poison, the properties of the biochemical components of these components, and the possible use in various fields of medicine and pharmacology [4–5]. However, there are almost no final data on the component composition, features of the effect and mechanisms of the pathological action of viper toxins on humans. The main reason for this fact is rather high cost of experimental studies related to the preparation of venom, followed by extended proteomic and transcriptomic analyses.

A comprehensive and multifactorial analysis of numerous data from experimental stu-

dies allows us to ascertain the extraordinary diversity of the molecular structure of toxins of various animal species, in particular vipers. Currently, the main pathogenetic vectors of the influence of their components on the human body and animals have been determined. First of all, this concerns the neuro- and hemovasotoxic effect of this poison [6–9]. Attention should be paid to the presence of data on damage to the respiratory, cardiovascular, digestive and urinary systems. Causing morphological changes in the cellular and tissue structures of these systems, toxins disrupt homeostasis, as well as normal physiological functions of the body. Taking into account the above, it is extremely important to consider research aimed at identifying new components of snake toxins, determining the degree of their impact on the affected organism and using the data obtained for the production of antidotes, and thereby eliminating economic losses associated with snake bites [10–15].

The purpose of the study is to establish the manifestations of jejunum damage under the conditions of common European adder (*Vipera berus berus*) poison action.

ANALYSIS OF RECENT RESEARCH

Despite the large number of publications devoted to the pathogenic effect of snake venom, changes in the small intestine after a snake bite, and in particular, a common viper, have not yet been sufficiently studied. Snake venoms are very complex mixtures of biologically active components that exert their effects using various mechanisms [16]. Enzymes, in particular proteinases, are among the most abundant molecules in the venom of many snakes, and they are often responsible for some of the clinical manifestations classically observed in viper envenomation. Hemotoxins of vipers contain serine proteases and metalloproteinases [17–19]. The first disrupt the processes of fibrinolysis and blood coagulation and cause the development of thrombosis, hemorrhages. Metalloproteinases affect the blood coagulation system or interact with such components of extracellular matrix

as collagen, elastin, laminin, fibronectin and destroy them [20–21].

According to the literature, the presence of three-loop viper toxins has been established. According to their chemical structure, they are proteins [22] that do not have an enzymatic effect. They are differentiated only by the length of the polypeptide chain, location and number of disulfide bonds. Three-loop toxins include cardiotoxins, muscarinic, α -neurotoxins. Their main effects are the effect on the central and peripheral nervous system, cardiotoxicity, cytotoxicity, inhibition of enzyme activity, hypotonic effect and change in platelet aggregation. The presence of so-called non-standard three-loop toxins – candoxin and bucandin – is presented. Their characteristic feature is a lower degree of toxicity compared to those mentioned above. Cytotoxins exert their effect through penetration into lysosomes, which contributes to the destabilization of the structure of these organelles, the release of proteases and the development of cell necrosis. Getting inside the nucleus, they interact with chromatin and start the process of programmed death [8; 11; 20].

MATERIALS AND RESEARCH METHODS

The experimental study was carried out in compliance with international recommendations on conducting medical and biological research using animals [23] in accordance with the «General principles of work on animals», approved by the 1st National Congress on Bioethics (Kyiv, Ukraine, 2001) and agreed with the provisions of the «European Convention on protection of vertebrate animals used for experimental and other scientific purposes» (Strasbourg, France, 1986). Compliance with the ethical principles of work is certified by the bioethics committee of the SRC «Institute of Biology and Medicine» of Taras Shevchenko National University, Kyiv (protocol No. 2 approved 19.08.2021).

Experimental rats were kept in vivarium conditions on a classical diet, with one animal per cage. Before the administration of substances to be investigated, experimental rats

underwent acclimatization in the conditions of a special room for conducting experiments for at least 5 days.

Rats were divided into 2 groups:

- 1 — control (a saline solution in a volume of 0.5 ml was administered intraperitoneally);
- 2 — rats were injected intraperitoneally with common European adder venom at an ED₅₀ dose of 1.576 µg/g.

Lyophilized *V. berus berus* crude venoms were obtained from V.N. Karazin Kharkiv National University (Kharkiv, Ukraine), kept at -20°C, dissolved in saline immediately before experiments, and centrifuged at 10,000 g for 15 min, and the supernatant was used.

After a day, the rats were withdrawn from the experiment by the method of sodium thiopental overdose and decapitation. All animals of both groups were weighed. Subsequently, the animals were dissected and macroscopic examination and description of all internal organs was carried out. Identified pathological changes were recorded and examined morphologically. Fragments of the small intestine were taken for microscopic examination. The pieces were fixed in a 10% formalin solution,

the duration of exposure did not exceed 1–2 days. The applied fixing solution prevented the process of autolysis, stabilized cells and tissues for their further processing and use in staining procedures. Next, the fragments were dehydrated in alcohols of increasing concentration, after which they were embedded in paraffin blocks. The prepared sections, 4–5 µm thick, were stained with hematoxylin and eosin. Histological preparations were examined under a SEO SCAN light microscope, images were processed using a Vision CCD Camera with an available image display system on a computer monitor [24].

RESULTS AND THEIR DISCUSSION

Microscopic examination of histological preparations of the wall of the jejunum of white rats after the injection of common European adder venom revealed destructive and degenerative changes in the membranes of the wall of the intestine. Compared with the group of intact animals, areas of the mucous membrane with a typical relief and areas with villi with significant destructive-degenerative disorders of the epithelial, own plates are preserved. Among the pathologically changed villi there are villi with an acute necrotic lesion of the epithelium and its complete desquamation. The villi are shortened, deformed and fused together and have the appearance of a polyp (Fig. 1).

The basement membrane of the tip of the villus is subject to the greatest destructive and degenerative changes. The epithelium in such areas loses its striated border, the nucleus of the epitheliocyte is compacted, basophilic, and the cytoplasm is strongly acidophilic. In areas of development of acute necrosis of villi, epithelial cells are rounded, lose their striated border. Their cytoplasm is richly acidophilic, and the nucleus is weakly basophilic, significantly increased in size. Within the epithelial layer of the villi there are cells where the nuclei have lost their contours and are subject to lysis. This indicates a rapid course of the processes of acute necrosis without a pyknotic stage. In the loose fibrous connective tissue in the villi near their apex, swelling is evi-

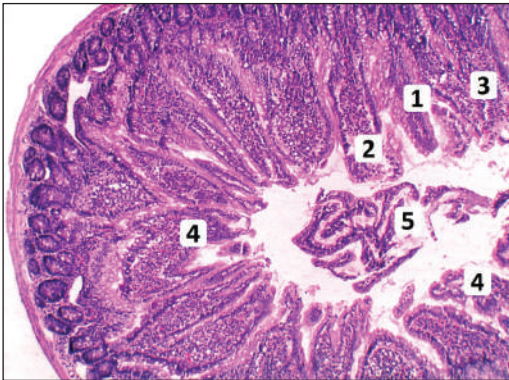


Fig. 1. Microscopic changes in the wall of the jejunum of white rats after the injection of common European adder venom

Note: 1 — villus with preserved normal histological structure, 2 — villus with desquamation of the epithelium, 3 — fused villi in the form of a polyp with desquamation of the epithelium, 4 — deformed villi, 5 — desquamated epithelial detritus in the intestinal lumen. Hematoxylin-eosin. ×100.

dent. The increased permeability of the hem capillary wall of the villi leads to pronounced hydration of the amorphous substance of the connective tissue of its stroma. Acidophilic bundles of collagen fibers form large cells with a small number of fibroblasts, lymphocytes, and macrophages. Fibroblastic and lymphohistiocytic infiltration of the stroma is observed in the stroma of thickened villi (Fig. 2). Changes in the intercellular substance include fibrous structures and the ground substance. Collagen, elastic and reticular fibers are compacted, forming a homogeneous acidophilic mass at the edges and weakly basophilic in the center. On the periphery of the foci of necrosis, there is significant leukocyte infiltration and a large number of macrophages-histiocytes.

The epithelial plate of the intestinal crypts undergoes much less destructive changes compared to the epithelium of the villi. But even these cells lose their striated border, single functional goblet cells, Paneth cells, remain. The cells of the crypts lose their characteristic shape, their cytoplasm is sharply basophilic, and the nuclei are condensed (Fig. 3). Single erythrocytes appear among the cells of the crypts. At the same time, a large number of cells with patterns of mitosis are observed in the area of the crypts.

Vessels of villi have undergone pathological changes, as a result their lumens are sharply expanded and blood-filled. In lumens there are erythrocytes and single leukocytes without visualization of clear boundaries between them. The vessel wall is thickened with pronounced perivascular edema, there is significant infiltration of lymphocytes, plasma cells, and neutrophils around the vessels, and there is a significant number of tissue basophils along the course of these vessels. The lumen of the hem capillaries is sharply expanded and filled with blood with aggregation of erythrocytes and the formation of single thrombi (Fig. 4). Violation of blood coagulation processes and violation of the integrity of the walls of the blood capillaries of the own lamina of the mucous membrane leads to the appearance of a moderate number of small hemorrhages in it.

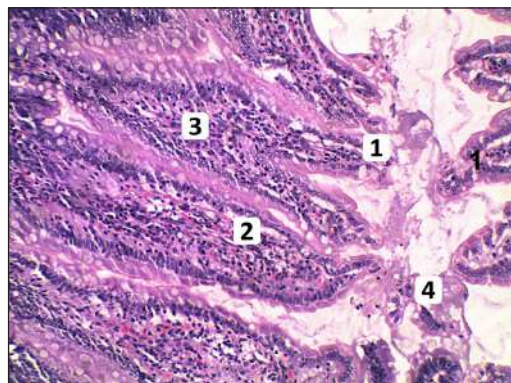


Fig. 2. Microscopic changes in the white rats jejunum wall after the injection of common European adder venom

Note: 1 – villus with desquamation of the epithelium, 2 – swelling of the stroma of the villi, 3 – histoleukocyte infiltration of the stroma, 4 – desquamated epithelial detritus in the intestinal lumen. Hematoxylin-eosin. $\times 200$.

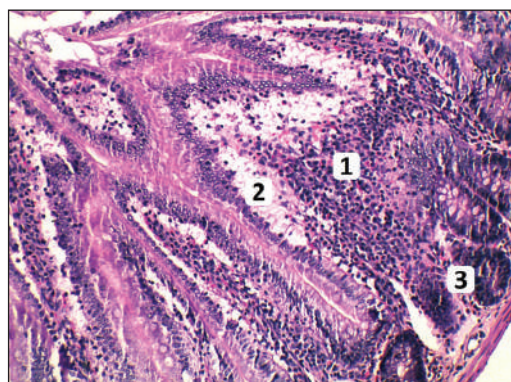


Fig. 3. Microscopic changes in the white rats jejunum wall after the injection of common European adder venom

Note: 1 – histoleukocyte infiltration of the villus, 2 – pronounced hydration of the amorphous substance of the villus stroma, 3 – intensively basophilic cells of the crypts. Hematoxylin-eosin. $\times 200$.

The muscular plate of the mucous membrane does not have clear boundaries, within the villi with destructive changes, smooth myocytes are disorganized, often lose their spindle-like shape, and their cytoplasm is brightly acidophilic. In the submucosa there is marked edema. There is disorganization of

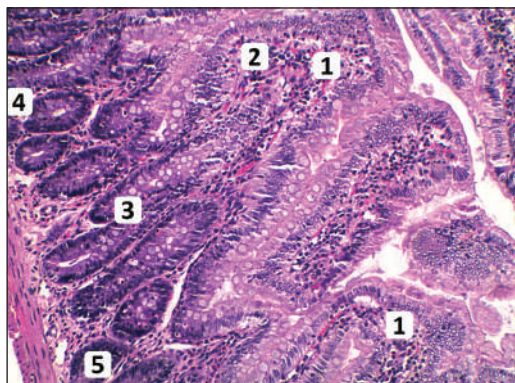


Fig. 4. Microscopic changes in the white rats jejunum wall after the injection of common European adder venom

Note: 1 – deformed villi, 2 – histoleukocyte infiltration, 3 – erythrocytes in the crypts, 4 – swelling of the submucosa stroma, 5 – basophilic, hyperchromic epithelial cells of the crypts. Hematoxylin-eosin. $\times 200$.

fibrous structures, an increase in the number of functionally active fibroblasts, macrophages and leukocytes is observed. Individual hemorrhages surrounded by lymphohistiocytic infiltration along their periphery are visualized along the course of the vessels (Fig. 5). The walls of the vessels themselves

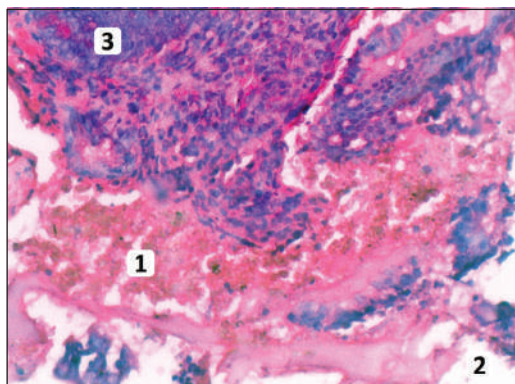


Fig. 5. Microscopic structure in the white rats jejunum wall after injection of common European adder venom.

Note: 1 – massive hemorrhage in the mucous membrane; 2 – edema of the stromal connective tissue; 3 – Lieberkühn crypt. Hematoxylin-eosin. $\times 400$.

are thickened with significant perivascular edema, significant lymphohistiocytic infiltration around the vessels.

In the serous membrane, there are bundles of collagen fibers with pronounced oxyphilic and an increase in the number of fibroblastic cells. Isolated hemorrhages are found in the muscular layer.

In the course of our research, the phenomena of rapid acute necrosis of the mucous membrane and, which attracted attention, without the existing pyknotic stage were revealed. The collagenous, reticular, and elastic fibers of the jejunal wall were swollen and compacted.

A decrease in the total protein content may be a consequence of necrotic cell death and the release of cell contents into the intracellular space. Cytotoxins of snake venom cause necrotic cell death. According to our data, widespread foci of necrosis with strong leukocyte infiltration were observed in the intestinal wall of experimental animals.

Bundles of collagen fibers with pronounced oxyphilic and an increase in the number of fibroblastic cells were noted in the serous membrane. There were isolated hemorrhages in the muscular shell. These destructive-degenerative changes in the intestinal wall are caused by the action of proteolytic enzymes of viper toxins, which cause the development of a local reaction, necrosis, and hemorrhagic edema. In addition, they have a fibrinolytic effect, increase blood coagulation, and activate the bradykinin system [19].

The study of cytotoxicity mechanism shows that cell death is caused by an increase in the permeability of the cytolemma for ions and the destruction of membranes. In addition, affecting erythrocytes, cause their hemolysis. This is fully confirmed by the results of our study: hemolysis of erythrocytes in the hem capillaries of the wall of the jejunum of rats with the appearance of numerous, from small to quite large, hemorrhages are noted.

The functional ability of platelets also changes, which is manifested in inhibition of their aggregation. The relationship between cytotoxins and the activation of cell apoptosis

by triggering the mitochondrial mechanism has been proven [25].

In this study, we demonstrated the morphological changes of the jejunum after intraperitoneal injection of snake venom. The obtained data indicate a highly toxic effect of snake venom on intestinal tissues and may reflect an additional pathogenic pathway in case of *Vipera berus berus* poisonings.

CONCLUSIONS

Histological studies of the small intestine of rats under the conditions of action of common European adder venom revealed:

1. The toxic substances of its venom cause destructive-degenerative changes in the re-

lief and stromal-vascular components of the mucous membrane of the organ in the wall of the jejunum: necrotic lesions and complete desquamation of the epithelium, loss of the striated border of enterocytes, fibroblastic and lymphoid infiltration of the villi's stroma.

2. Increased permeability of the vessel walls of the microcirculatory channel due to the pronounced hydration of the connective tissue's amorphous substance, thinning and complete destruction of the walls of hemocapillaries together with the cytotoxic effect of the poison on erythrocytes leads to the formation of multiple and small hemorrhages with hemolysis of erythrocytes.

ЛІТЕРАТУРА

- Aird S.D. Introduction to the Toxins Special Issue on Identification and Functional Characterization of Novel Components. *Toxins (Basel)*. 2020. Vol. 12 (5). P. 336. DOI: <https://doi.org/10.3390/toxins12050336>
- Zhang Y. Why do we study animal toxins? *Dongwuxue Yanjiu*. 2015. Vol. 36(4). P. 183–222. DOI: <https://doi.org/10.13918/j.issn.2095-8137.2015.4.183>
- Pach S., Geyt J.L., Gutierrez J.M. et al. Paediatric snakebite envenoming: the world's most neglected «Neglected Tropical Disease»? *Archives of Disease in Childhood*. 2020. Vol. 105 (12). P. 1135–1139. DOI: <https://doi.org/10.1136/archdischild-2020-319417>
- Bolon I., Durso A.M., Mesa S.B. et al. Identifying the snake: First scoping review on practices of communities and healthcare providers confronted with snakebite across the world. *PLoS One*. 2020. Vol. 15 (3). P. e0229989. DOI: <https://doi.org/10.1371/journal.pone.0229989>
- Muselin F. Protein structure of the venom in nine species of snake: from bio-compounds to possible healing agents. *Brazilian Journal of Medical and Biological Research*. 2020. Vol. 53 (1). P. e9001. DOI: <https://doi.org/10.1590/1414-431X20199001>
- Amazonas D.R., Portes-Junior J.A., Nishiyama-Jr M.Y. et al. Molecular mechanisms underlying intraspecific variation in snake venom. *Journal of Proteomics*. 2018. Vol. 181. P. 60–72. DOI: <https://doi.org/10.1016/j.jprot.2018.03.032>
- Cristina R.T., Kocsis R., Tulcan C. et al. Protein structure of the venom in nine species of snake: from bio-compounds to possible healing agents. *Brazilian Journal of Medical and Biological Research*. 2020. Vol. 53 (1). P. e9001. DOI: <https://doi.org/10.1590/1414-431X20199001>
- Nirthanan S. Snake three-finger α -neurotoxins and nicotinic acetylcholine receptors: Molecules, mechanisms and medicine. *Biochemical Pharmacology*. 2020. Vol. 181. P. 114168. DOI: <https://doi.org/10.1016/j.bcp.2020.114168>
- Siigur J., Aaspolu A. and Siigur E. Biochemistry and pharmacology of proteins and peptides purified from the venoms of the Snakes *Macrovipera lebetina* subspecies. *Toxicon*. 2019. Vol. 158. P. 16–32. DOI: <https://doi.org/10.1016/j.toxicon.2018.11.294>
- Alekseeva A.S., Tretiakova D.S., Chernikov V.P. et al. Heterodimeric *V. nikolskii* phospholipases A2 induce aggregation of the lipid bilayer. *Toxicon*. 2017. Vol. 133. P. 169–179. DOI: <https://doi.org/10.1016/j.toxicon.2017.05.015>
- Doltchinkova V., Stoylov S. and Angelova P.R. Viper toxins affect membrane characteristics of human erythrocytes. *Biophysical Chemistry*. 2021. Vol. 270. P. 106532. DOI: <https://doi.org/10.1016/j.bpc.2020.106532>
- Latinović Z., Leonardi A., Koh C.Y. et al. The procoagulant snake venom serine protease potentially having a dual, blood coagulation factor V and X-Activating activity. *Toxins*. 2020. Vol. 12 (6). P. 358. DOI: <https://doi.org/10.3390/toxins12060358>
- Hermansen M.N., Krug A.H. and Brabrand M. Envenomation by the common European adder (*Vipera berus*): a case series of 219 patients. *European Journal of Emergency Medicine*. 2019. Vol. 26 (5). P. 362–365. DOI: <https://doi.org/10.1097/MEJ.0000000000000577>
- Zinenko O., Tovstukha I. and Korniyenko Y. PLA2 Inhibitor Varespladib as an Alternative to the Antivenom Treatment for Bites from Nikolsky's Viper *Vipera berus nikolskii*. *Toxins (Basel)*. 2020. Vol. 12 (6). P. 356. DOI: <https://doi.org/10.3390/toxins12060356>
- Paolino G., Nicola M.R.D., Pontara A. et al. Viper snakebite in Europe: a systematic review of a neglected disease. *Journal of the European Academy of Dermatology and Venereology*. 2020. Vol. 34 (10). P. 2247–2260. DOI: <https://doi.org/10.1111/jdv.16722>
- Boda F., Banfai K., Garai K. et al. Effect of *Vipera ammodytes* Snake Venom on the Human Cytokine Network. *Toxins (Basel)*. 2018. Vol. 10 (7).

- P. 259. DOI: <https://doi.org/10.3390/toxins10070259>
17. Di Nicola M. R., Pontara A., Kass G. E. et al. Vipers of Major clinical relevance in Europe: Taxonomy, venom composition, toxicology and clinical management of human bites. *Toxicology*. 2021. Vol. 453. P. 152724. DOI: <https://doi.org/10.1016/j.tox.2021.152724>
 18. Kalogeropoulos K., Treschow A.F., auf dem Keller U. et al. Protease activity profiling of snake venoms using high-throughput peptide screening. *Toxins*. 2019. Vol. 11 (3). P. 170. DOI: <https://doi.org/10.3390/toxins11030170>
 19. Yee K.T., Tongsima S., Vasieva O. et al. Analysis of snake venom metalloproteinases from Myanmar Russell's viper transcriptome. *Toxicon*. 2018. Vol. 146. P. 31–41. DOI: <https://doi.org/10.1016/j.toxicon.2018.03.005>
 20. Hiu J.J. and Yap M.K.K. Cytotoxicity of snake venom enzymatic toxins: Phospholipase A2 and l-amino acid oxidase. *Biochemical Society Transactions*. 2020. Vol. 48 (2). 719–731. DOI: <https://doi.org/10.1042/BST20200110>
 21. Kadi-Saci A. and Laraba-Djebari F. Purification and characterization of a thrombin-like enzyme isolated from *Vipera lebetina* venom: its interaction with platelet receptor. *Blood Coagulation & Fibrinolysis*. 2020. Vol. 31 (1). P. 1–10. DOI: <https://doi.org/10.1097/MBC.0000000000000856>
 22. Tasoulis T. and Isbister G.K. A review and database of snake venom proteomes. *Toxins*. 2017. Vol. 9 (9). P. 290. DOI: <https://doi.org/10.3390/toxins9090290>
 23. Добреля Н.В., Бойцова Л.В., Данова І.В. Правова база для проведення етичної експертизи доклінічних досліджень лікарських засобів з використанням лабораторних тварин. *Фармакологія та лікарська токсикологія*. 2015. № 2. С. 95–100.
 24. Горальський Л.П., Хомич В.Т., Кононський О.І. Основи гістологічної техніки і морфофункціональні методи досліджень у нормі та при патології: навч. посіб. Житомир: «Полісся», 2005. 288 с.
 25. Santhosh M.S., Thushara R.M., Hemshekhar M. et al. Alleviation of viper venom induced platelet apoptosis by crocin (*Crocus sativus*): implications for thrombocytopenia in viper bites. *Journal of Thrombosis and Thrombolysis*. 2013. Vol. 36 (4). P. 424–432. DOI: <https://doi.org/10.1007/S11239-013-0888-X>

REFERENCES

1. Aird, S.D. (2020). Introduction to the Toxins Special Issue on Identification and Functional Characterization of Novel Components. *Toxins (Basel)*, 12 (5), 336. DOI: <https://doi.org/10.3390/toxins12050336> [in English].
2. Zhang, Y. (2015). Why do we study animal toxins? *Dongwuxue Yanjiu*, 36 (4), 183–222. DOI: <https://doi.org/10.13918/j.issn.2095-8137.2015.4.183> [in English].
3. Pach, S., Geyt, J.L., Gutierrez, J.M. et al. (2020). Paediatric snakebite envenoming: the world's most neglected «Neglected Tropical Disease»? *Archives of Disease in Childhood*, 105 (12), 1135–1139. DOI: <https://doi.org/10.1136/archdischild-2020-319417> [in English].
4. Bolon, I., Durso, A.M., Mesa, S.B. et al. (2020). Identifying the snake: First scoping review on practices of communities and healthcare providers confronted with snakebite across the world. *PLoS One*, 15 (3), e0229989. DOI: <https://doi.org/10.1371/journal.pone.0229989> [in English].
5. Muselin, F. (2020). Protein structure of the venom in nine species of snake: from bio-compounds to possible healing agents. *Brazilian Journal of Medical and Biological Research*, 53 (1), e9001. DOI: <https://doi.org/10.1590/1414-431X20199001> [in English].
6. Amazonas, D.R., Portes-Junior, J.A., Nishiyama-Jr, M.Y. et al. (2018). Molecular mechanisms underlying intraspecific variation in snake venom. *Journal of Proteomics*, 181, 60–72. DOI: <https://doi.org/10.1016/j.jprot.2018.03.032> [in English].
7. Cristina, R.T., Kocsis, R., Tulcan, C. et al. (2020). Protein structure of the venom in nine species of snake: from bio-compounds to possible healing agents. *Brazilian Journal of Medical and Biological Research*, 53 (1), e9001. DOI: <https://doi.org/10.1590/1414-431X20199001> [in English].
8. Nirthanan, S. (2020). Snake three-finger α -neurotoxins and nicotinic acetylcholine receptors: Molecules, mechanisms and medicine. *Biochemical Pharmacology*, 181, 114168. DOI: <https://doi.org/10.1016/j.bcp.2020.114168> [in English].
9. Siigur, J., Aaspolu, A. & Siigur, E. (2019). Biochemistry and pharmacology of proteins and peptides purified from the venoms of the Snakes *Macrovipera lebetina* subspecies. *Toxicon*, 158, 16–32. DOI: <https://doi.org/10.1016/j.toxicon.2018.11.294> [in English].
10. Alekseeva, A.S., Tretiakova, D.S., Chernikov, V.P. et al. (2017). Heterodimeric *V. nikolskii* phospholipases A2 induce aggregation of the lipid bilayer. *Toxicon*, 133, 169–179. DOI: <https://doi.org/10.1016/j.toxicon.2017.05.015> [in English].
11. Doltchinkova, V., Stoylov, S. & Angelova, P.R. (2021). Viper toxins affect membrane characteristics of human erythrocytes. *Biophysical Chemistry*, 270, 106532. DOI: <https://doi.org/10.1016/j.bpc.2020.106532> [in English].
12. Latinović, Z., Leonardi, A., Koh, C.Y. et al. (2020). The procoagulant snake venom serine protease potentially having a dual, blood coagulation factor V and X-Activating activity. *Toxins*, 12 (6), 358. DOI: <https://doi.org/10.3390/toxins12060358> [in English].
13. Hermansen, M.N., Krug, A.H. & Brabrand, M. (2019). Envenomation by the common European adder (*Vipera berus*): a case series of 219 patients. *European Journal of Emergency Medicine*, 26 (5), 362–365. DOI: <https://doi.org/10.1097/MEJ.0000000000000577> [in English].
14. Zinenko, O., Tovstukha, I. & Korniyenko, Y. (2020). PLA2 Inhibitor Varespladib as an Alternative to the

- Antivenom Treatment for Bites from Nikolsky's Viper *Vipera berus nikolskii*. *Toxins (Basel)*, 12 (6), 356. DOI: <https://doi.org/10.3390/toxins12060356> [in English].
15. Paolino, G., Nicola, M.R.D., Pontara, A. et al. (2020). Vipera snakebite in Europe: a systematic review of a neglected disease. *Journal of the European Academy of Dermatology and Venereology*, 34 (10), 2247–2260. DOI: <https://doi.org/10.1111/jdv.16722> [in English].
 16. Boda, F., Banfai, K., Garai, K. et al. (2018). Effect of *Vipera ammodytes* Snake Venom on the Human Cytokine Network. *Toxins (Basel)*, 10 (7), 259. DOI: <https://doi.org/10.3390/toxins10070259> [in English].
 17. Di Nicola, M.R., Pontara, A., Kass, G.E. et al. (2021). Vipers of Major clinical relevance in Europe: Taxonomy, venom composition, toxicology and clinical management of human bites. *Toxicology*, 453, 152724. DOI: <https://doi.org/10.1016/j.tox.2021.152724> [in English].
 18. Kalogeropoulos, K., Treschow, A.F., auf dem Keller, U. et al. (2019). Protease activity profiling of snake venoms using high-throughput peptide screening. *Toxins*, 11 (3), 170. DOI: <https://doi.org/10.3390/toxins11030170> [in English].
 19. Yee, K.T., Tongsimma, S., Vasieva, O. et al. (2018). Analysis of snake venom metalloproteinases from Myanmar Russell's viper transcriptome. *Toxicon*, 146, 31–41. DOI: <https://doi.org/10.1016/j.toxicon.2018.03.005> [in English].
 20. Hiu, J.J. & Yap, M.K.K. (2020). Cytotoxicity of snake venom enzymatic toxins: Phospholipase A2 and l-amino acid oxidase. *Biochemical Society Transactions*, 48 (2), 719–731. DOI: <https://doi.org/10.1042/BST20200110> [in English].
 21. Kadi-Saci, A. & Laraba-Djebari, F. (2020). Purification and characterization of a thrombin-like enzyme isolated from *Vipera lebetina* venom: its interaction with platelet receptor. *Blood Coagulation & Fibrinolysis*, 31 (1), 1–10. DOI: <https://doi.org/10.1097/MBC.0000000000000856> [in English].
 22. Tasoulis, T. & Isbister, G.K. (2017). A review and database of snake venom proteomes. *Toxins*, 9 (9), 290. DOI: <https://doi.org/10.3390/toxins9090290> [in English].
 23. Dobrelia, N.V., Boitsova, L.V. & Danova, I.V. (2015). Pravova baza dlia provedennia etychnoi ekspertyzy doklinichnykh doslidzhen likarskykh zasobiv z vykorystanniam laboratornykh tvaryn [Legal basis for ethical examination of preclinical studies of drugs using laboratory animals]. *Farmakolohiia ta likarska toksykolohiia — Pharmacology and Drug Toxicology*, 2, 95–100 [in Ukrainian].
 24. Horalskyi, L.P., Khomych, V.T. & Kononskyi, O.I. (2011). *Osnovy histolohichnoi tekhniki i morfofunktsionalni metody doslidzhen u normi ta pry patolohii [Fundamentals of histological technique and morphofunctional research methods in normal and pathology]*. Zhytomyr: Polissya [in Ukrainian].
 25. Santhosh, M.S., Thushara, R.M., Hemshekar, M. et al. (2013). Alleviation of viper venom induced platelet apoptosis by crocin (*Crocus sativus*): implications for thrombocytopenia in viper bites. *Journal of Thrombosis and Thrombolysis*, 36 (4), 424–432. DOI: <https://doi.org/10.1007/S11239-013-0888-X> [in English].

Стаття надійшла до редакції журналу 09.01.2023