

PSEUDARTHROSIS OF THE CARPAL SCAPHOID TREATED WITH NON-VASCULARIZED CORTICOCANCELLOUS BONE GRAFT

Omar Mourafiq, Valery Kamenan, Youssef Benyias, Jalal Boukhriss, Bouchaib Chefry,
Driss Bencheba, Ahmed Salim Bouabid, Moustapha Boussouga

Department of Orthopaedic Surgery & Traumatology II, Mohamed V Military Hospital, Rabat 10000, Morocco
Faculty of Medicine and pharmacy, Rabat 10000, Morocco
Mohamed V University, Rabat 10000, Morocco

Abstract: Objectives: To carry out an epidemiological study and to assess the evolutionary profile of patients with scaphoid non-union treated by anterior non-vascularized corticocancellous bone graft.

Introduction: The non-union is a serious complication of carpal scaphoid fractures. Untreated, it leads to instability and osteoarthritis of the carp. The most used technique is that of Matti-Russe employing a corticocancellous graft.

Materials and methods: We report in this retrospective study the experience of the department of Orthopaedic Surgery & Traumatology II, Mohamed V Military Hospital, Rabat, in the treatment of non-unions of the carpal scaphoid by anterior non-vascularized corticocancellous graft in nine cases collected between January 2012 and March 2016. We identified six cases of stage IIA and three cases of stage IIB. All our patients were operated by the Matti-Russian technique followed by an immobilization by plaster cast cuff on three months.

Results: All our patients achieved a union within an average of three months. The Mayo Wrist score was excellent in 66.6% of cases. Our results were very satisfying in 90% of cases, satisfying in 10%.

Conclusion: The treatment of non-unions of the carpal scaphoid without necrosis or osteoarthritis, using anterior non-vascularized bone graft remains the most widely used technique. The presence of initial instability is a factor of poor prognosis, its correction reduces the risk of arthritis.

Keywords: *Carpal scaphoid – the non-union- surgery-Matti-Russe technique.*

Problem statement and analysis of recent research. Several surgical techniques have been described in the literature, to treat the non-union of carpal scaphoid, their indication depends on the site of the initial fracture and whether or not there is instability, osteoarthritis, or necrosis [1].

In 1936, when Matti [2] describes his technique of treatment of non-union scaphoid, he recommends a dorsal way. In 1960, Russian [3] modified the principle of this operation by using an anterior way that was less likely to damage the vascularization of the scaphoid. Since then, this palmar approach of the scaphoid is admitted by the majority of authors.

Materials and methods

The authors report a retrospective study of nine cases of carpal non-union without osteoarthritis or necrosis, treated with non-vascularized corticocancellous bone graft. These patients were trained at the Traumatology-Orthopedics Unit II of the Military Teaching Hospital Mohamed V, over a period of four years, from January 2012 to March 2016. Patients with associated lesions such as a peri-lunar dislocation and with advanced osteoarthritis, or necrosis were excluded.

All our patients are men, with an average age of 23 years old, all of them are manual workers. The dominant side was reached in three cases. According to the classification of Alnot et al. We have identified six cases of stage IIA (presence of geodes, without intra-carpal instability) and three cases of stage IIB (presence of geodes with intracarpal instability in DISI (Dorsal intercalated segment instability)).

According to Schernberg's classification: Six cases had a high corpal fracture (type II), or 67%, two cases had a low corpal fracture (type III) or 22%, one case had a superior polar fracture (type I) or 11%. The average time between initial trauma and the diagnosis of non-union is 16.5 months. In eight of nine cases, 89%, the initial carpal scaphoid fracture was

unnoticed. In one of our patients, non-unions of the carpal scaphoid resulted from failure of orthopedic treatment. In no case in our series, non-unions of the carpal scaphoid were secondary to failure of surgical treatment. An MRI of the preoperative wrist was performed twice to eliminate bone necrosis.

Our patients were operated by several operators, according to the Matti-Russe technique, anteriorly, excision of the non-union site (Fig1, Fig2), with the placement of a cortico-cancellous graft taken from the ipsilateral iliac crest, osteosynthesis using

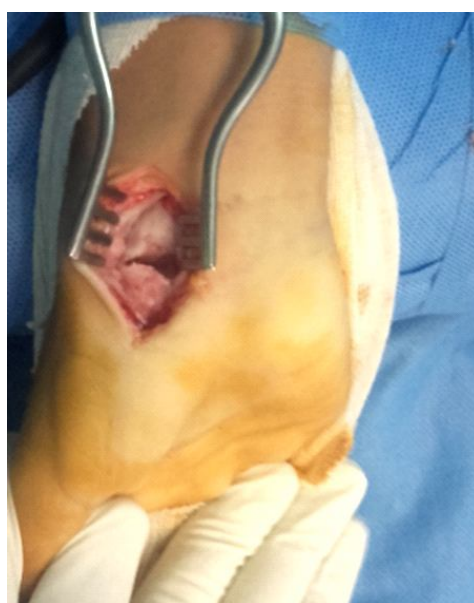

Fig. 1. Anterior arthrotomy and exposure of the non-union source

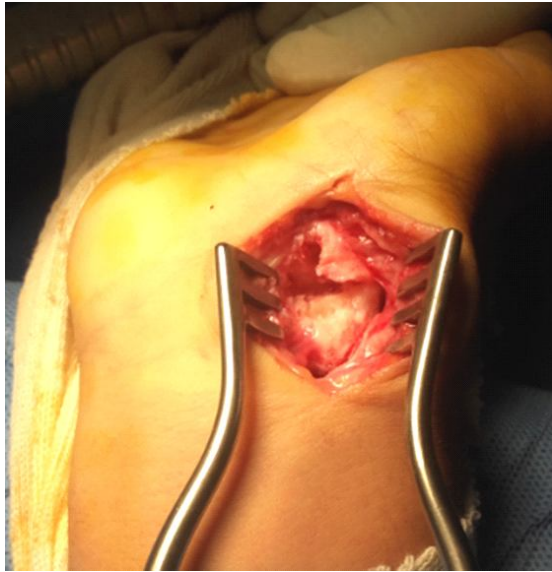

Fig. 2. Healing of the site and digging of a trench

two pins is recommended in order to stabilize the assembly (Fig3), and postoperative immobilization in plaster splint for three months. The clinical outcomes were evaluated according to the Michon score [4]. The pain was assessed in five stages. The flexion and extension mobilities were compared with the contralateral side.

The union, the correction of instability, and the occurrence or not of styloscaphoid, radioscapoid or lunocapital osteoarthritis were assessed radiologically.

The study methods were based on the use of medical records with the collection of clinical examination data, radiological, surgical and evolutionary data of these patients.

Results

All our patients achieved a union within an average of three months. According to the Michon score, there were 55.5% excellent outcomes, and 33.3% good outcomes. Eight of our patients had an improvement in the range of motion and recovery of grip strength after surgery and functional rehabilitation. Only one patient had a limitation of the range of motion with an extension of 60 to 70 on the contralateral side, bending 60 to 65, ulnar inclination 25 to 37, radial inclination 10 to 21, and grip strength at 60%. All our patients were painful preoperatively, all our patients were relieved, eight totally and one partially. Radiologically, three patients in our study had instability in Dorsal Intercalated Segment Instability, the alignment of the carp bones of the other six patients was respected. All our patients had a correct correction of intra-carpal instability and restoration of scaphoid.

Discussion

The fractures of the scaphoid were unnoticed in eight patients of our series, this is why the early diagnosis of any wrist trauma is very important. In our study, all our patients consolidated after a first intervention after an average of three months (12 weeks), which is close to the literature data [5, 6]. In parallel with these good results in union, only one case of wrist

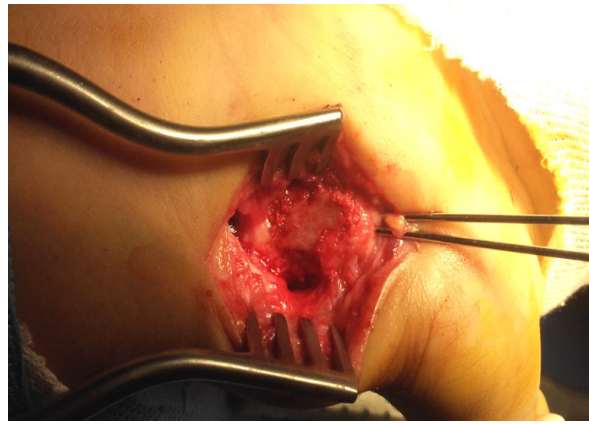


Fig. 3. The cortico-cancellous graft taken from the ipsilateral iliac crest, is embedded in the non-union center with complementary stabilization by two pins

stiffness was noted in our study and little complications are reported in the literature: Idou et al. [7] report a case of Reflex Sympathetic Dystrophy Syndrome (RSDS).

The study of listed cases in our archives between January 2012 and December 2016 about “nine cases” is weak compared to literature data. This small number of cases would be explained by either a low recruitment of non-union, indicating better management in our formation of carpal scaphoid fractures, or many cases that are unnoticed and which will be discovered by chance may be in osteoarthritic stages with repercussions on the function or even on the socio-professional level.

In our study stabilization by osteosynthesis (two fine axial pins, introduced by the tubercle of the scaphoid and fixed in the proximal fragment), was for us indispensable in stage II.

But other techniques exist. Conventional screws occupy a large volume and are technically difficult to implement [1]. The anterior position of the pins is opposed to the plication of the scaphoid, and it makes it unnecessary for some authors, [8] the use of a cortico-cancellous graft, then replaced by a spongy iliac pure impacted graft.

The site of the fracture, the time between initial trauma and surgery, are prognostic factors that are variously appreciated in the literature [1]. The existence of preoperative instability in DISI is a factor of poor prognosis [6, 9, 10, 11, 12, and 13]. The correction of the DISI (Dorsal intercalated segment instability) and the restoration of the normal height of the scaphoid must be done carefully [14].

Conclusion

According to the Alnot classification, the corticocancellous graft and spindle synthesis treatment using the Matti-Russe technique in non-union of the carpal scaphoid stage IIA and IIB, without osteoarthritis and without necrosis, gave good outcomes in our study, where there was union among all our patients, 90% of them were very satisfied with the functional results. Therefore, this technique remains a chosen technique in the treatment of nonunion of the carpal scaphoid without osteoarthritis and without necrosis, although some authors prefer vascularized bone grafts with equally satisfactory outcomes.

References

1. Bellec Y, Le, Alnot J-Y. Treatment of non-unions of the carpal scaphoid using a nonvascularised corticocancellous bone graft: A retrospective series of 47 cases. *Chirurgie de la main*. 2008; 27: 154-159.
2. Matti H. Technik und resultate meiner pseudarthrosen-operation. *Z chir*. 1936; 63:1442-1453.
3. Russe O. Fractures of the carpal navicular. Diagnosis, non-operative treatment, and operative treatment. *J Bone Joint Surg*. 1960; 42 A: 759-768.
4. Michon J. Fractures and pseudarthroses of the carpal scaphoid, *Rev Chir Orthop*. 1972; 58:649-815.
5. Passuti N, Waast D, Pietu G, Gouin F. Complications of bone consolidation: nonunion, *Revue de chirurgie orthopédique et traumatologique*. 2004 ; 90 (5), 160. doi : RCO-09-2004-90-S5-0035-1040-101019-ART178.
6. Herbert TJ, Fischer WE. Management of the fractured scaphoid using a new bone screw. *J Bone Joint Surg Br*. 1984; 66:114-123.
7. Idou O, Martin B, Gomis R. Retrospective study of a series of thirty-three pseudarthroses of the carpal scaphoid by intervention of Matti-Russe. *La Main*. 1996; 1:291-298.
8. Bellemire Ph. Pseudarthrosis of the carpal scaphoid: Spongy graft and pinning. *Sauramps medical*. 2004;247-53
9. Hooning Van Duyvenbode JFF, Keijser LCM, Hauet EJ, Obermann WR, Rozing PM. Pseudarthrosis of the scaphoid treated by the Matti-Russ operation. *J Bone Joint Surg*. 1991;73B:603-6.
10. Jiraneck WA, Ruby K, Millender LB, Banroff MS, Newberg AH. Long term results after Russe bone grafting: the effect of malunion of the scaphoid. *J Bone Joint Surg*. 1992;74A:8-16.
11. Nakamura R, Imadea T, Tsuge S, Watanabe K. Scaphoid non-union with DISI deformity. *J Hand Surg*. 1991;16B:156-61.
12. Huene DR, Huene DS. Treatment of nonunion of the scaphoid with the Ender compression blade plate system. *J Hand Surg [Am]*. 1991;16:913-22.
13. Tomaino MM, King J, Pizillo M. Correction of lunate malalignment when bone grafting scaphoid nonunion with humpback deformity: rational and results of a technique revisited. *J. Hand Surg [Am]*. 2000;25:322-9.
14. Linscheid RL, Dobins JH, Cooney WP. Volar wedge grafting of the carpal scaphoid in non-unions associated with dorsal instability patterns. *J Bone Joint Surg*. 1982;64:632-3.

Received: 04.12.2018

Revised: 18.12.2018

Accepted: 19.12.2018