

# Clinical case of squamous cell carcinoma of ovarian dermoid cyst

DOI 10.52739/bio-up.1.2021.3-7

Ihor I. Chermak<sup>1</sup>, Volodymyr I. Chermak<sup>2</sup>, Bogdan Ya. Serbin<sup>3</sup>,  
Kateryna S. Gurska<sup>4</sup>, Sergiy G. Gychka<sup>4</sup>

## ABSTRACT

Cases of squamous cell carcinoma of the dermoid cyst of the ovaries are rare in comparison with other pathological processes of the ovaries, which is why they are of great interest not only to medical scientists who face such cases, but also for targeted medical cooperation. We review the literature, publications and one clinical case so that specialists who come into contact with it have a clearer idea of the course of the disease, its morphological aspects, which in the future will facilitate the diagnosis. The problem of this pathology is an example of discussion, and therefore the number of scientific works of our foreign colleagues is devoted to it.

<sup>1</sup> Bogomolets National Medical University, Department of Obstetrics and Gynecology of the Institute of Postgraduate Education, Kyiv, Ukraine

<sup>2</sup> Kyiv Medical University, Department of Obstetrics and Gynecology, Kyiv, Ukraine

<sup>3</sup> Kyiv Medical University, Department of Pathological Anatomy, Histology and Forensic Medicine, Kyiv, Ukraine

<sup>4</sup> Bogomolets National Medical University, Department of Pathological Anatomy #2, Kyiv, Ukraine

**Key words:** dermoid cyst, squamous cell carcinoma, ovarian cancer.

## LITERATURE REVIEW

A large number of cases of squamous cell carcinoma of the ovarian dermoid cyst were published at the end of the last century [1,2,3,4].

Recent research [5] presented a study of 17 clinical cases from 1983–2005 of this pathology. The median age was 55 years (median 54.8; range 37–75). Eight cases were stage I, 5 were stage II, and 4 were stage III. The average tumor size is 14.2 cm. All patients underwent surgery. Ten patients received adjuvant treatment — 6 chemotherapy and 4 chemoradiotherapy. Six patients had recurrent pelvic disease after adjuvant therapy. Four patients died from the disease. The overall annual survival rate was 60 %. 4 patients with stages IA-IIB disease who received adjuvant platinum-based chemotherapy and radiation therapy survived after 12–56 months of follow-up. The authors concluded that the prognosis strongly depends on the stage at which the surgery was performed. And also that platinum-based chemotherapy with pelvic irradiation may be a reasonable adjuvant therapy in the early stages of the disease. In 2008 their colleagues [6] published an article on the prediction and treatment of squamous cell carcinoma in ovarian dermoid cyst. The study analyzed 220 cases of pathology from 1976 to 2005, namely, such parameters as the age of patients, clinical and laboratory data, degree of disease, tumor markers, treatment, survival under various conditions (188 of 220 were included in the analysis of survival — cases with surgical stage). Most often, the disease occurred in elderly women (on average  $55.0 \pm 14.4$  years), cysts were large (on average  $13.7 \pm 5.7$  cm). Abdominal pain (71.6%) was the most common symptom. Preoperative serum SCC antigen levels were high (81.3%). The overall 5-year survival rate at all stages was 48.4 %. For stage I, the 5-year survival rate was 75.7 %; Stage II — 33.8 %; Stage III — 20.6 %; and IV stage — 0% ( $p < 0.0001$ ). Further research into treatment options at all stages has shown that postoperative adjuvant chemotherapy can improve survival for both stage III and IV. However, postoperative radiation therapy did not show this effect. Mul-

tivariate analysis showed that stage and optimal mass removal were significant factors affecting survival. As a result, it was found that mature cystic teratoma should be treated as early as possible. The stage of the tumor and optimal removal of the tumor are critical to survival.

In 2019, Congcong Li et al [9] presented an analysis of 435 cases from PubMed. The mean age of diagnosis was 53.5 (range 19–87) years old. The most common clinical manifestations were abdominal pain (47.3 %) and abdominal mass (26.0 %). Stage I, II, III and IV accounted for 50.0, 18.8, 26.8 and 4.4% of all cases, respectively. Patients with stage I had significantly better prognosis than stage II, III and IV patients ( $P < 0.01$ ). Hysterectomy can improve overall survival ( $P < 0.01$ ). It was concluded that hysterectomy and platinum-based chemotherapy are associated with better survival. Fertility-sparing surgery is feasible for young patients with early stage.

## CLINICAL CASE REVIEW

In medical practice, squamous cell carcinoma of the ovarian dermoid cyst is an infrequent clinical case, so it is of great value to observe each such clinical case. We can observe a rare feature — the formation of "adult" type of malignant teratoma cancer — the development of secondary malignancy.

Patient K., 55 years old, was admitted to the gynecology department in a surgical hospital on September 2, 2020 with complaints of several years of pain in the lower abdomen, menopause for 4.5 years. In anamnesis - pelvic bone injury, blood transfusion, metal osteosynthesis of pelvic bones (2009), as well as bilateral cystectomy for ovarian dermoid cysts, cervical polypectomy (2011).

On the ECG from September 2, 2020 detected: a slight deviation of the electrical axis of the heart to the left, depression of the ST-segment, lower diaphragmatic myocardial ischemia. As a result of ultrasound of the pelvic organs (September 2, 2020) revealed endometrioid cyst of the right ovary with a dermoid component. On the CT examination from December 2, 2019 in the area of the right ovary

the fat-containing education, the sizes 52 x 33 mm (on research from December 28, 2009 to 75 mm, in the anamnesis of removal of the specified education), in the conclusion — a teratoma of the right ovary is visualized. On the ultrasound of the pelvic organs from June 30, 2020 the right ovary is represented by an echo (-) formation with heterogeneous structure, 52 x 42 mm in size.

Clinical diagnosis: Cyst of the right ovary. Endometrial polyp. Secondarily altered appendix. OMM malignancy.

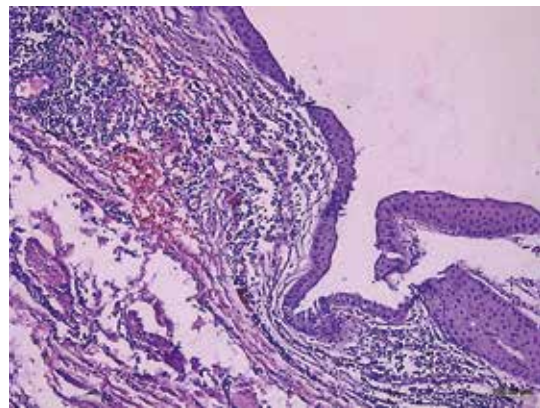
The surgery was performed September 3, 2020 (surgical access — laparoscopy) in the amount of pangysterectomy, adhesiolysis, appendectomy involved in the connective process hyperemic appendicular process. The right ovary in the form of a cyst, measuring 10.0 x 7.0 cm, soldered to the peritoneum of the small pelvis and the posterior surface of the uterus. The content of the multichambered cyst: 1) dermoid (hair, fat), 2) dermoid (fat), 3) dense solid component, up to 3.0 cm in size, no internal growths were detected.

Macroscopically, the right ovary is represented by a large rounded cyst up to 5 cm in diameter, filled with atheromic masses. The wall of the cyst is of uneven thickness with areas of whitish-red compaction, which alternate with areas of yellow. The inner surface is rough with whitish growths. Ovarian tissue with atrophic changes.

Microscopic examination of the surgical material reveals a cyst lined with squamous epithelium with areas of its desquamation (Figure 1). The cyst wall is represented by connective tissue with focal angiomas. The expressed chronic inflammatory infiltration represented by lymphocytes, histiocytes, plasma cells among which there are also multinucleated giant cells is defined. In the wall of the cyst there are areas of hemorrhage, fibrinoid changes, calcification (Figure 2). In some areas of epithelial expulsion areas of hyperplasia and moderate dysplasia of the squamous epithelium are identified (Figure 3). In areas of thickening of the wall of the dermoid cyst are identified areas of multifocal infiltrative growth of the tumor, represented by atypical squamous epithelial cells (Figure 4). Peripherally, areas of tumor growth are determined

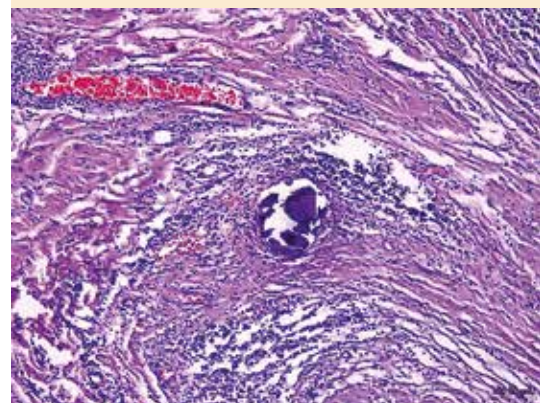
by lymphocytic infiltration. Zones of infiltrative growth border on the foci of necrosis of tumor tissue (Fig. 5).

Thus, in the long-standing dermoid cyst of the ovary on the background of chronic inflammation, hyperplastic processes developed in the lining squamous epithelium with the development of dysplasia, and later - malignancy with the appearance of squamous cell carcinoma. Infiltrative tumor growth was accompanied by the formation of necrosis and an inflammatory reaction involving the adjacent organs (appendix, fallopian tube).



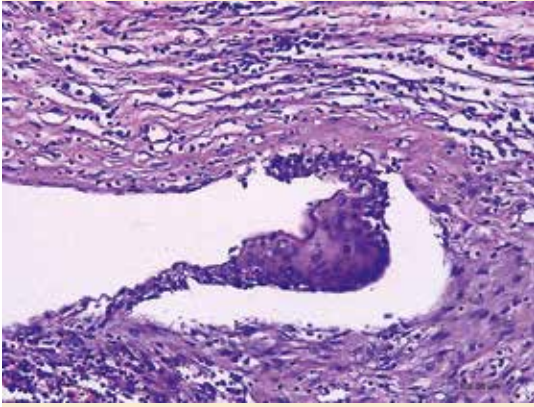
**Figure 1.** The wall of the dermoid cyst of the ovary, lined with multilayered squamous epithelium.

H&E staining. X100.



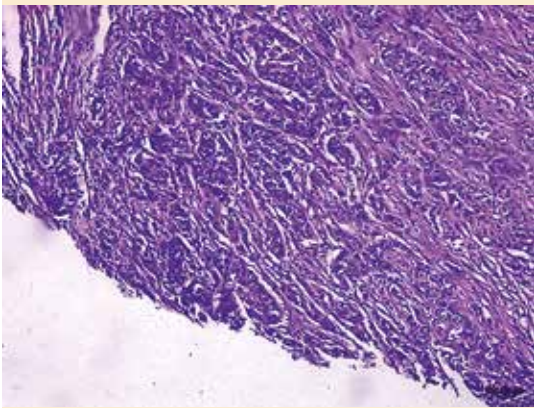
**Figure 2.** Expressed inflammatory infiltration in the wall of the dermoid cyst with a site of calcification.

H&E staining. X100.



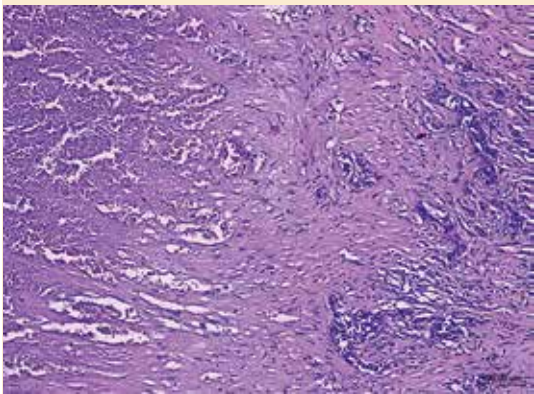
**Figure 3.** The area of dysplasia of the lining squamous epithelium in the dermoid cyst of the ovary.

H&E staining. X100.



**Figure 4.** Area of infiltrative growth of squamous cell carcinoma in the wall of the dermoid cyst of the ovary.

H&E staining. X100.



**Figure 5.** The area of necrosis in the area of growth of squamous cell carcinoma in the wall of the dermoid cyst of the ovary.

H&E staining. X100.

The patient was discharged on September 8, 2020 (on the 5th day after surgery) in satisfactory condition. Thus, the chosen tactics of examination and treatment improved the condition of a patient with a rare disease — squamous cell carcinoma of the dermoid cyst of the ovary.

## CONCLUSIONS

Based on the researches and clinical case studied, we can conclude that squamous cell carcinoma of the ovarian dermoid cyst, a disease characteristic of women after menopause, is often asymptomatic. The case of malignant transformation of the dermal ovarian cyst into squamous cell carcinoma is quite rare. This is why the treatment of such cases is not standardized, but it is argued that the most effective combination chemotherapy based on platinum. In some of the presented retrospective analyzes [7,8] of 20+ cases, clinical cases were also mentioned when, after surgery (unilateral salpingo-oophorectomy) in patients younger than the average age of morbidity, a successful pregnancy was noted without relapse. We can also confirm the dependence of the prognosis on age, the tumor size, the stage of diagnosis of the disease, and vascular invasion.

In any case, the issue requires further research to establish a standard of treatment and prognosis, which is currently limited by the rarity of the disease. The problem of squamous cell carcinoma of the ovarian dermoid cyst is quite relevant for the medical community.

## REFERENCES

1. WF Peterson . Malignant degeneration of benign cystic teratomas of the ovary: a collective review of the literature. *Obstet Gynecol*, 12 (1957), pp. 793–830.
2. G Ribeiro, P Hughesdon, E Wiltshaw. Squamous carcinoma arising in dermoid cysts and associated with hypercalcemia: a clinicopathologic study of six cases. *Gynecol Oncol*, 29 (1988), pp. 222–230.
3. T. Hirakawa, M. Tsuneyoshi, M Enjoji. Squamous cell carcinoma arising in mature cystic teratoma of the ovary. Clinicopathologic and topographic analysis. *Am J Surg Pathol*, 13 (1989), pp. 397-405.
4. Tseng C.J., Chou H.H., Huang K.G. Squamous cell carcinoma arising in mature cystic teratoma of the ovary. *Gynecol. Oncol.* 1996; 63(3): 364–370.
5. Dos Santos L., Mok E., Iasonos A, Park K, Soslow R. A., Aghajanian C, Alektiar K, Barakat RR, Abu-Rustum NR. Squamous cell carcinoma arising in mature cystic teratoma of the ovary: a case series and review of the literature. *Gynecol Oncol.* 2007; 105(2): 321–4.
6. Chen RJ, Chen KY, Chang TC, Sheu BC, Chow SN, Huang SC. Prognosis and treatment of squamous cell carcinoma from a mature cystic teratoma of the ovary. *J Formos Med Assoc.* 2008; 107(11): 857, 868.
7. Sakuma M, Otsuki T, Yoshinaga K, et al. Malignant transformation arising from mature cystic teratoma of the ovary: a retrospective study of 20 cases. *Int J Gynecol Cancer.* 2010; 20(5): 766, 771.
8. Avci S, Selcukbiricik F, Bilici A, Ozkan G, Ozagari AA, Borlu F. Squamous cell carcinoma arising in a mature cystic teratoma. *Case Rep Obstet Gynecol.* 2012; 2012: 314, 535.
9. Li, C., Zhang, Q., Zhang, S. et al. Squamous cell carcinoma transformation in mature cystic teratoma of the ovary: a systematic review. *BMC Cancer* 19, 217 (2019).

**Corresponding author:** Kateryna S. Gurska, katarzynagurski@gmail.com

Manuscript was received on 25 October; accepted for publication on 26 December.

**CITE AS:** IHOR I. CHERMAK ET AL. CLINICAL CASE OF SQUAMOUS CELL CARCINOMA OF OVARIAN DERMOID CYST

BIOMEDICAL UPDATE, ISSUE 1, 2021