

## ЗАМІТКИ ІЗ ПРАКТИКИ

DOI: 10.21802/gmj.2020.1.9

Majid Jehangir<sup>1</sup>, Abha Mariam<sup>1</sup>, Ramandeep Singh<sup>2</sup>, Ankit Prabhakar<sup>1</sup>**Primary Alveolar Hydatid Disease: A Rare Case Series with Review of Imaging Findings**<sup>1</sup>Department of Radiology, Government Medical College, Srinagar, Jammu and Kashmir, India<sup>2</sup>Veterinary Pathology, Sher-e-Kashmir University of Agricultural Science and Technology of Kashmir, Shalimar, Srinagar, Jammu and Kashmir, IndiaE-mail: [rs14021@gmail.com](mailto:rs14021@gmail.com)

**Abstract.** Alveolar hydatid disease is a rare but potentially fatal parasitic infection caused by *Echinococcus multilocularis*. To the best of our knowledge, only few cases have been reported from India till date. We present 6 cases of pathologically proven alveolar hydatid disease with review of imaging findings.

**The objective** of this case series was to share our experiences of pitfalls in diagnosis of alveolar hydatid disease.

**Materials and Methods.** The study was conducted in Post Graduate Department of Radiodiagnosis and Imaging, Government Medical College, Srinagar, Jammu and Kashmir. Our study was conducted between 6<sup>th</sup> January 2017 to 22<sup>nd</sup> May 2019. A total of 6 patients were taken up for study. The patients were evaluated clinically and investigated using the relevant imaging modalities. Diagnosis was confirmed by histopathologic examination following core biopsy of lesion.

**Results.** There were two males and four females with most of patients in age group of 20 to 40 years. Imaging findings in our cases suggest that typical radiological appearance of alveolar hydatid disease can be summarized as an irregular hypoattenuating mass lesion having typical calcifications (can be peripheral, as well as central) with tiny cystic components.

**Keywords:** *alveolar hydatid disease; Echinococcus multilocularis; imaging*

**Introduction**

Hydatid disease is a zoonotic parasitic infection caused by larval stage of *Echinococcus* species. It has two forms - cystic echinococcosis which is more common and caused by *E. granulosus* and alveolar echinococcosis which is a rare entity caused by *E. multilocularis*. Alveolar hydatid disease is limited to northern hemisphere with most of the cases reported from China [1-3]. Only few cases have been reported from India till date [4-6]. We present a rare series of six cases of pathologically proven alveolar hydatid disease from Kashmir region of North India with review of imaging findings.

**The objective** of this case series was to share our experiences of pitfalls in diagnosis of alveolar hydatid disease.

**Materials and Methods**

The study was conducted in Post Graduate Department of Radiodiagnosis and Imaging, Government Medical College, Srinagar, Jammu and Kashmir. Our study was conducted between 6<sup>th</sup> January 2017 to 22<sup>nd</sup> May 2019. A total of 6 patients were taken up for study.

The patients were evaluated clinically and investigated using the relevant imaging modalities. Diagnosis was confirmed by histopathologic examination following core biopsy of lesion. All patients received long-term anthelmintic therapy. There were two males and four females with most of patients in age group of 20 to 40 years.

**Results***Case 1*

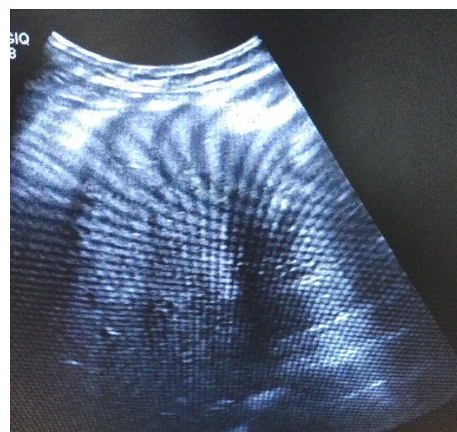A 50-year-old male without a comorbidity presented with a two-month history of pain in the epigastric and right hypochondriac regions. General physical examination was

unremarkable. Hematological and biochemical investigations were within normal limits. Ultrasonography (USG) revealed a large mass lesion involving the left lobe of the liver with areas of hyper- and hypoechogenicity and few foci of calcification (Fig 1).

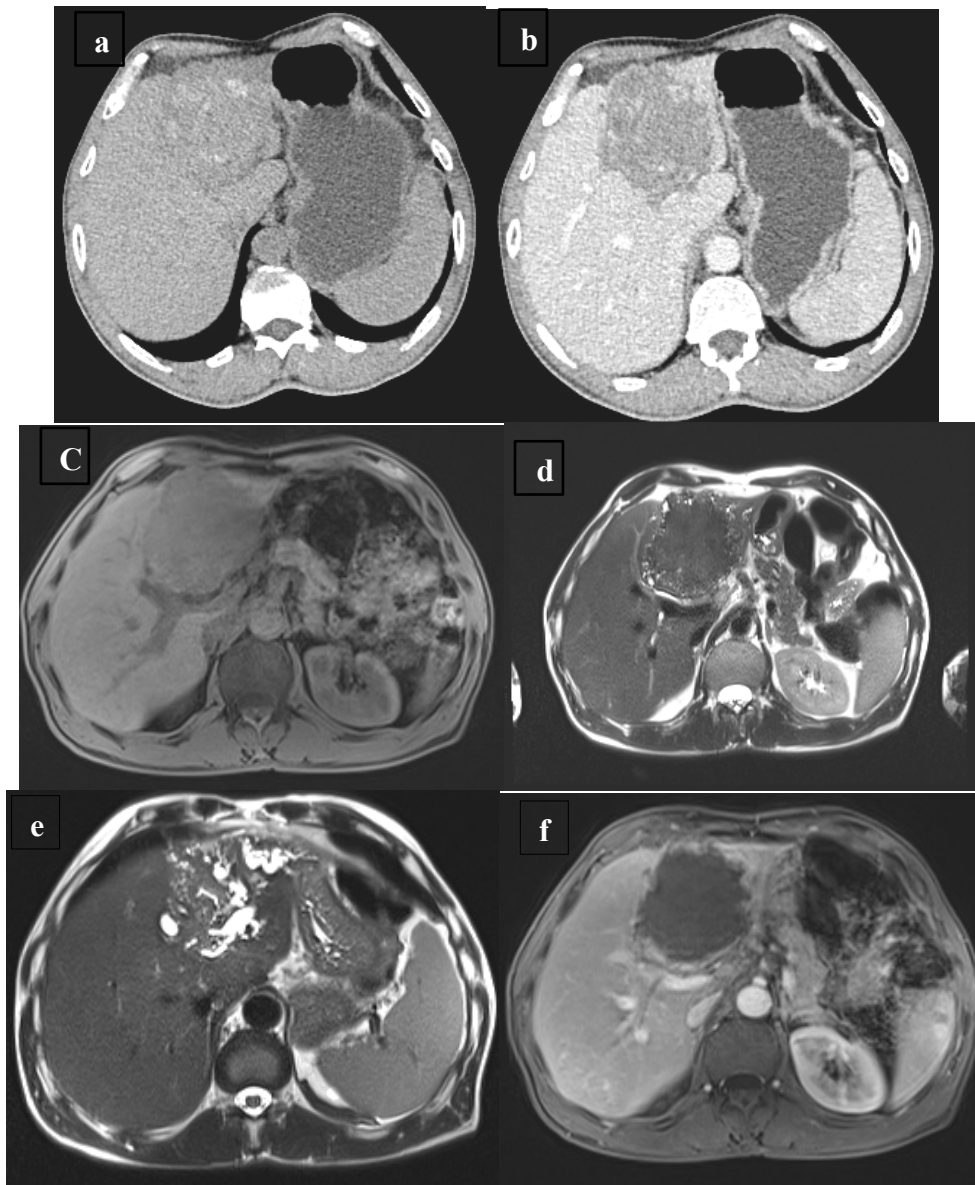
The patient underwent contrast enhanced computed tomography (CT) scan which showed a hypodense mass lesion measuring 7.7x7x6.5 cm involving segment IV and extending into segment III of the liver with intralesional calcification, focal dilatation of left lobe biliary radicles and capsular retraction. Postcontrast scan did not reveal any enhancement of the lesion; however, delayed phase images showed mild peripheral enhancement (Fig. 2a, b). The left branch of portal vein and the left hepatic vein were narrowed due to mass effect. On magnetic resonance imaging (MRI), the lesion was hypointense on both T1W and T2W images with peripheral focal T2 hyperintensities suggestive of cystic components. Delayed capsular enhancement was seen on postcontrast images (Fig. 2 c-f). Based on CT and MRI findings, differential diagnosis of intrahepatic cholangiocarcinoma and alveolar hydatid disease was offered. Alpha-fetoprotein (AFP) levels were within normal limits. Serology for *Echinococcus* was positive with immunoglobulin (IgG) levels of 16.6 NTU (NovaTec Units). Following this, hepatic ultrasound-guided biopsy was carried out, and the specimen was sent for histopathological examination (HPE). Microscopic features revealed deranged liver architecture with necrotic areas containing laminated membranes surrounded by inflammatory exudates and granulation tissue forming peri cyst. The portal tracts showed mixed inflammatory infiltrates with necrotic debris surrounding portal structures with degenerating membranes. Sinusoids were dilated. All these features were consistent with alveolar hydatid disease (Fig. 3a, b).

*Case 2*

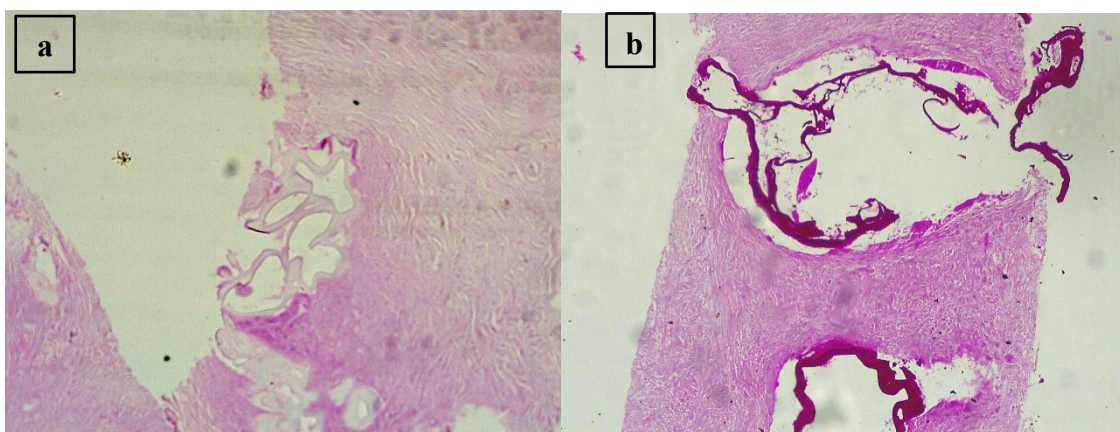
A 36-year-old female presented with a history of vague abdominal pain for 5 months. Physical examination and baseline investigations were within normal limits. USG was done which



**Fig. 1.** Abdominal grayscale US image showing a heterogeneous mass lesion in the left lobe of the liver. The mass was generally isoechoic; however, it contained hyperechoic foci of calcification



**Fig. 2.** Alveolar echinococcosis in a 50-year-old man: (a) abdominal axial non-enhanced image showing a hypoattenuating mass-like lesion with irregular margins and scattered hyperattenuating foci of calcification; (b) faint enhancement of fibroinflammatory components surrounding the parasitic cyst in the portal venous phase. MRI findings in the same patient: axial unenhanced T1-weighted (c) and T2-HASTE (d) images showing a mass-like lesion in the liver with hypointense signal on both sequences with foci of peripheral T2 hyperintensities representing cystic components and dilated left lobe intrahepatic biliary radicles (e) due to extrinsic compression; delayed capsular enhancement was seen on postcontrast images (f)



**Fig. 3.** Photomicrograph (periodic acid-Schiff stain) showing deranged liver architecture with liver parenchyma infiltrated by multiple irregular cysts (a) with darkly stained laminar membranes (b)

showed a well-defined heterogeneously hyperechoic mass lesion involving the right lobe of the liver. CT showed a well-defined hypodense solid mass lesion measuring approximately 9.6x6.5cm in segment VI and VII with central calcification. No post-contrast enhancement was noted (Fig. 4a-c). Serology for Echinococcus was negative. Following this, MRI was performed which revealed a well-defined T2 hyperintense lesion with multiple T2 hyperintensities representing cystic components (Fig. 4d). Ultrasound-guided fine needle aspiration cytology (FNAC) was performed and the specimen, sent for HPE, was suggestive of E. multilocularis infection.

**Case 3**

A 24-year-old female reported a two-year history of dull abdominal pain. Physical examination revealed a palpable lump in the right hypochondriac region; rest of the examination was unremarkable. Laboratory parameters were within normal limits, except for mild leukocytosis. USG demonstrated heterogenous mass lesions with indistinct borders in both lobes of the liver and multiple scattered foci of calcification (Fig. 5a). Contrast-enhanced CT was done which revealed two predominantly hypodense lesions involving segment VIII, IVa and IVb measuring 6.7x6.2cm in segment VIII and 7.8x5.9cm in segment IVa and IVb, respectively. Central hyperattenuation was noted in both lesions consistent with calcifications. No post-contrast enhancement was noted (Fig. 5b, c). Based on USG and CT findings, diagnosis of calcified hydatid cyst was made; however, serology for Echinococcus was negative, therefore, hepatic ultrasound-guided biopsy was performed and the specimen was sent for HPE, which revealed features consistent with alveolar hydatid disease of the liver. Surgical resection of liver lesions was done, and the patient is doing well on follow-up.

**Case 4**

A 27-year-old female presented with a history of vague abdominal pain for 5 months. Physical examination and baseline investigations were within normal limits. CT scan showed a hypodense mass lesion involving segment VII, VI infiltrating the porta hepatis with intralesional calcifications and focal dilatation of right lobe biliary radicles. No post-contrast enhancement was noted (Fig. 6 a-c). MRI images (Fig. 7 a-c) showed a mass-like lesion in the liver with hypointense signal on both sequences with foci of peripheral T2 hyperintensities representing cystic components, dilated right lobe intrahepatic biliary radicles probably due to mass effect. Ultrasound-guided biopsy was done and the specimen, sent for HPE, was suggestive of E. multilocularis infection.

**Case 5**

A 20-year-old male presented with complaints of pain in the right hypochondriac region for four years. Physical examination was unremarkable. Baseline investigations were within normal limits. Chest X-ray showed a calcified lesion inferior to the right hemidiaphragm in the right upper quadrant (Fig. 8a). USG revealed a highly calcified mass lesion in the right lobe of the liver. CT scan was performed, and it revealed a hypodense mass lesion with irregular borders and peripheral foci of calcification involving segment V and VIII. No post-contrast enhancement was seen (Fig. 8b, c). Calcified hydatid cyst of the liver was diagnosed. HPE was performed, and it revealed diagnosis of hepatic alveolar hydatid infection.

**Case 6**

A 40-year-old female presented with bilateral lower limb weakness for one month. Physical examination showed brisk ankle and knee reflexes with hypertonia and rigidity in both lower limbs. Baseline laboratory parameters were within normal limits. MRI was done for further evaluation which revealed a cystic lesion involving D9 vertebral body and left pedicle with associated epidural intracanalicular component causing significant canal stenosis and cord compression (Fig. 9a, b). Differential diagnosis of giant cell tumor and osteoblastoma was offered. Following this, surgical excision of lesion with D9 laminectomy was carried out and the specimen was sent for histopathological examination which showed laminated membranes consistent with alveolar hydatid infection. Serology for hydatid disease was, however, negative. Albendazole was prescribed for 5 weeks. Later on, she presented with recurrence of disease.

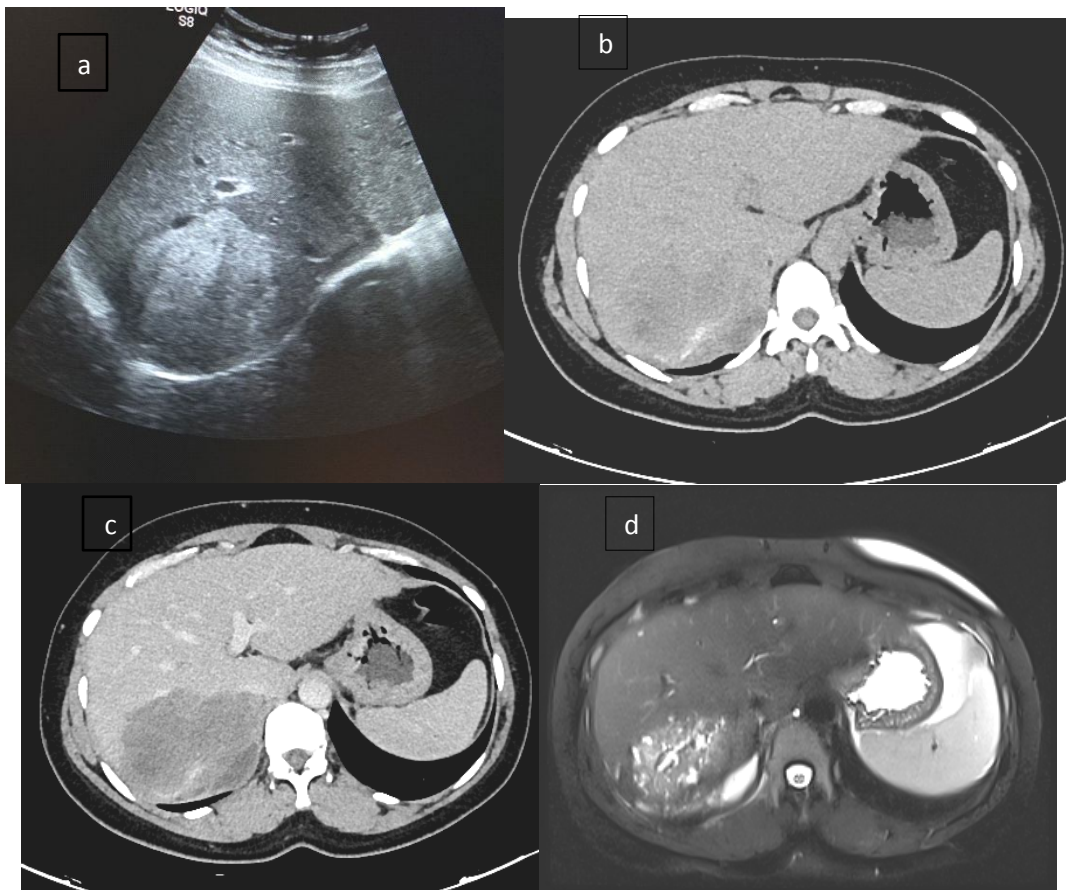
These cases have been summarised in Table 1.

**Discussion**

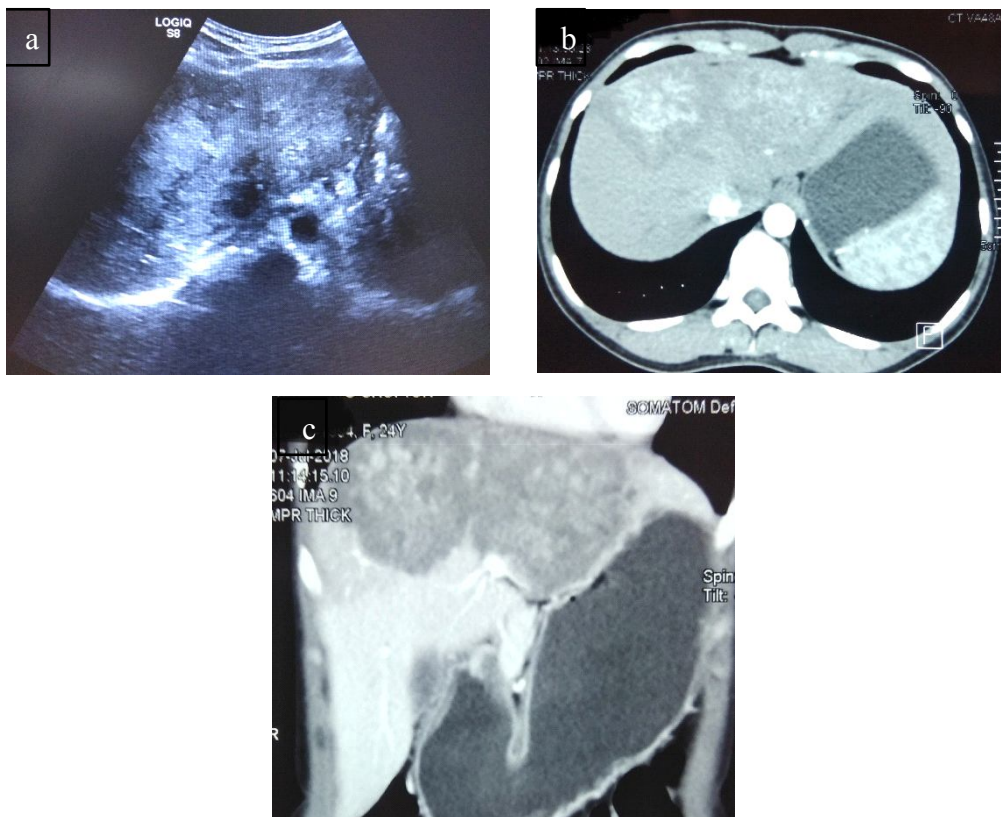
Hydatid disease caused by E. granulosus has a worldwide distribution and is endemic in many areas including Kashmir region of India. Bashir Ahmad Fomda from Sher-i-Kashmir Institute of Medical Sciences, Kashmir, India conducted an epidemiological study to determine seroprevalence of hydatid infection in Kashmir. In this study, 72 (5%) out of 1,429 samples tested, were positive for E. granulosus infection; however, no sample was positive for E. multilocularis [7]. In 1978, B.K Aikat et al. from Post Graduate Institute reported one case in a patient of Kashmiri ethnicity, that incidentally was the first ever description of its occurrence in India. In this case report, they described the hepatic lesion infiltrated into the right atrial wall resembling an atrial tumor. The ostium of the inferior vena was

**Table 1. Patients with alveolar hydatid disease**

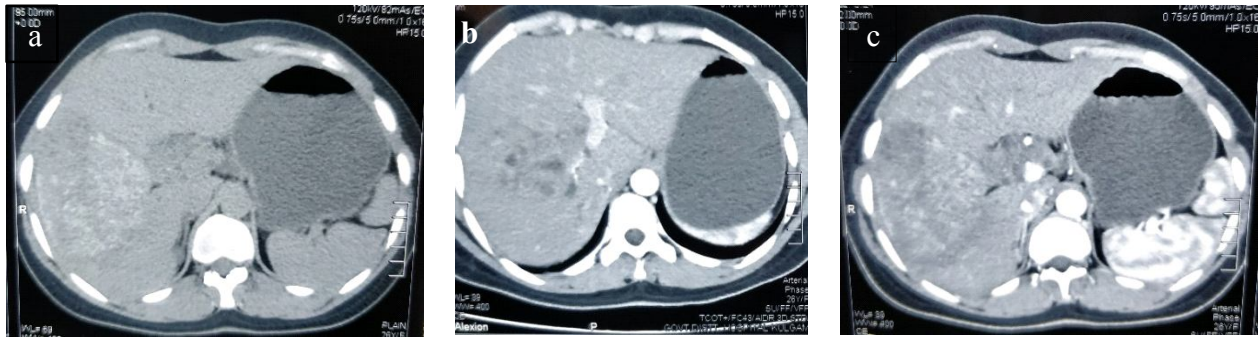
Age	Sex	Clinical presentation	Imaging findings	Final diagnosis	Outcome
50	Male	Abdominal pain	Hypodense lesion with intralesional calcifications on CT, hypointense on both T1 and T2 on MRI with peripheral T2 hyperintensities (cysts)	Alveolar hydatid disease	Anthelmintic chemotherapy; doing well on follow-up
36	Female	Abdominal pain	Hypodense solid mass lesion with central calcification, hyperintense on T2 with multiple tiny cysts	Alveolar hydatid disease	Anthelmintic chemotherapy; doing well on follow-up
24	Female	Abdominal pain	Hypodense lesions with central calcifications	Alveolar hydatid disease	Surgical resection; doing well on follow-up
27	Female	Abdominal pain	Hypodense lesion with intralesional calcifications and infiltrating into the porta hepatis on CT, hypointense on both T1 and T2 on MRI with peripheral T2 hyperintensities (cysts)	Alveolar hydatid disease	Anthelmintic chemotherapy; doing well on follow-up
20	Male	Abdominal pain	Hypodense lesion with diffuse peripheral calcifications	Alveolar hydatid disease	Lost to follow up
40	Female	Bilateral lower limb weakness	Cystic lesion in D9 vertebral body and left pedicle with intracanalicular extension	Alveolar hydatid disease	Laminectomy with removal of cystic lesion; later, the patient presented with recurrence



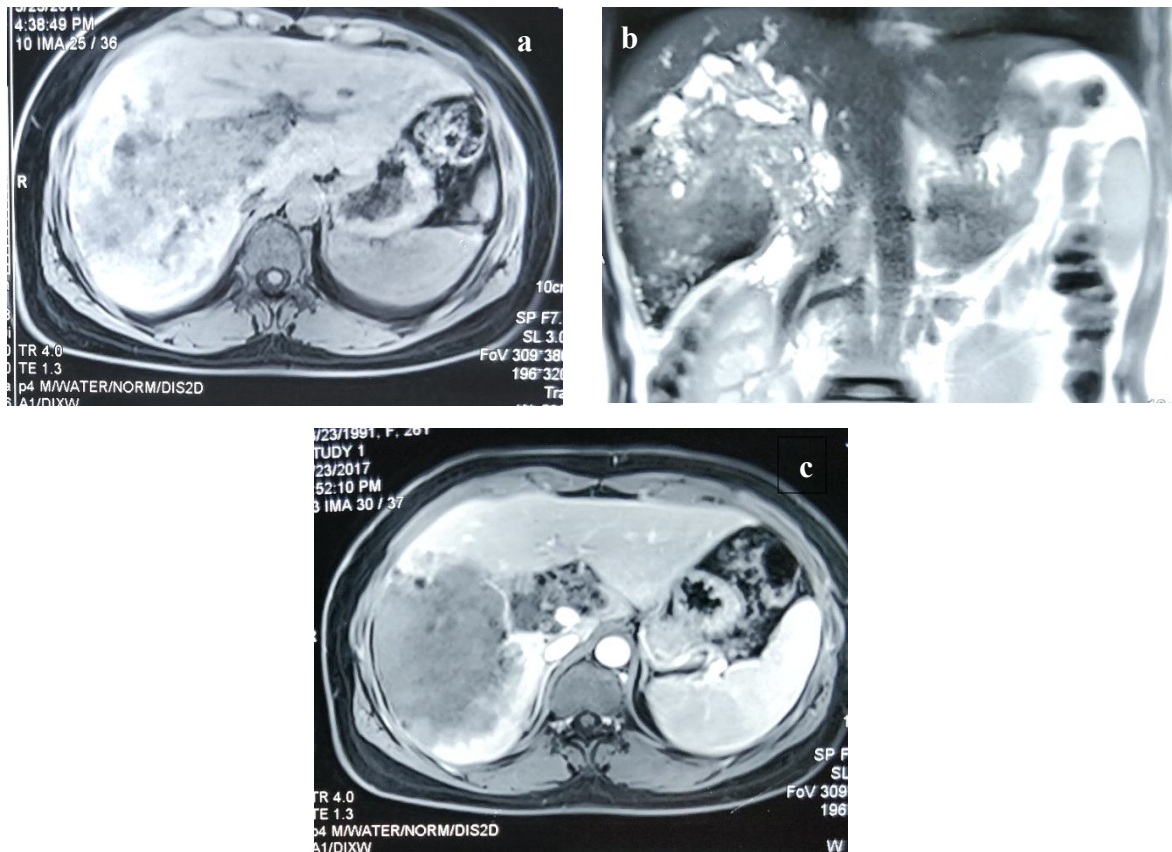
**Fig. 4.** (a) Oblique sonogram showing a hyperechoic lesion involving the right lobe of the liver; axial non-contrast (b) and postcontrast (c) CT demonstrating a hypodense mass-like lesion in the right lobe of the liver with central calcification and no enhancement on postcontrast scan; (d) T2 HASTE MRI sequence demonstrating predominantly hyperintense lesion containing multiple cystic areas



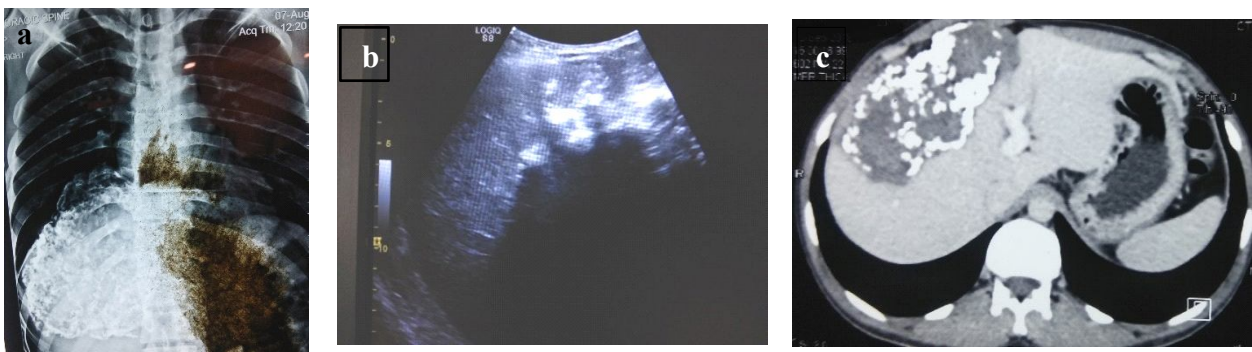
**Fig. 5.** Alveolar echinococcosis in a 24-year-old female: (a) abdominal grayscale US showing a heterogeneous mass lesion involving both the right and left liver lobes; (b) axial contrast-enhanced CT image showing hypodense lesions with irregular margins and central calcifications; (c) coronal reformatted image demonstrating the involvement of segment VIII and IV



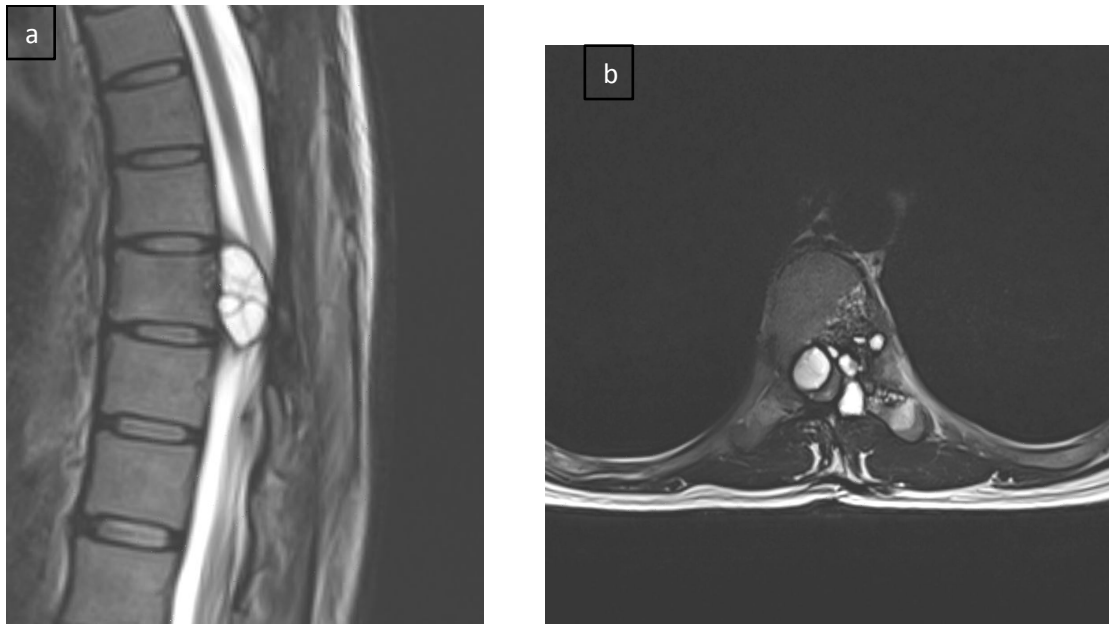
**Fig. 6.** (a) Axial non-contrast, (b) and (c) contrast-enhanced CT scan showing a hypodense mass lesion involving segment VII, VI and infiltrating into the porta hepatis with intralesional calcification and focal dilatation of right lobe biliary radicles. No post-contrast enhancement was noted



**Fig. 7.** Axial unenhanced T1-weighted (a) and coronal T2-HASTE (b) images showing a mass-like lesion in the liver with hypointense signal on both sequences with cystic components and dilated right lobe intrahepatic biliary radicles. Axial MR images (c) obtained after the administration of intravenous contrast medium showed no enhancement within the mass



**Fig. 8.** (a) Frontal radiograph showing a calcified lesion in the right upper quadrant; (b) grayscale US image showing a highly calcified mass lesion with strong posterior acoustic shadowing; (c) axial contrast enhanced CT showing a hypodense mass lesion with irregular borders and dense foci of calcifications involving segment V and VIII. No post-contrast enhancement was seen



**Fig. 9. Spinal alveolar hydatid disease in a 40-year-old female: (a) sagittal and (b) axial T2-weighted images showing a cystic lesion involving D9 vertebra and left pedicle with intracanalicular extension causing significant canal stenosis**

occluded causing Budd-Chiari syndrome. Diagnosis of alveolar hydatid disease was made on autopsy [4].

Alveolar hydatid disease is caused by larva (metacestode) of the fox tapeworm, *E. multilocularis*. It requires two hosts to complete its life cycle. The definitive hosts are foxes, while rodents are the intermediate hosts.

Humans are accidental hosts and become infected either by direct contact with a definite host or by consuming contaminated food/water. The larvae reach the liver after penetrating the intestinal wall through the portal and lymphatic systems, where they develop and form tumor-like buds giving rise to multiple vesicles with a germinal layer surrounded by the laminar membrane. Granulomatous inflammatory host response occurs, which surrounds the lesion. Fibrosis is also commonly seen, causing compression of the major vessels and bile ducts. There is progressive infiltration into the host tissue leading to formation of large mass with central necrosis and peripherally active process. This pattern mimics invasive carcinoma.

This infiltrative pattern of growth is not seen in *E. granulosus* when there is a well-defined fibrous capsule [1-3, 8].

Clinical features are most commonly associated with epigastric pain and jaundice; however, features of cholangitis, portal hypertension and biliary cirrhosis may occur due to vascular/biliary invasion [9].

Diagnosis is usually based on the combination of clinical, radiological, serological and histopathological findings. Nowadays, the usage of species-specific antigens such as Em2 and Em2 plus (combination of Em2 with recombinant protein) have proved to be quite valuable in determining the causative agent. Other diagnostic molecules include Em18, Em13, Em10, purified alkaline phosphatase [3, 10-14].

Alveolar hydatid disease is associated with high fatality and poor prognosis. Radical surgery is the treatment of choice; however, in unresectable cases, therapy with benzimidazole anthelmintic agents is usually mandatory [3].

#### *Classification and Staging*

Similar to the Tumor-Node-Metastasis (TNM) Classification of Malignant Tumors, the PNM Classification of Malignant Tumors has been developed by the European Network for Concerted Surveillance of Alveolar Echinococcosis and the

WHO Informal Working Group on Echinococcosis. This is primarily based on imaging findings. It determines the number of parasites present, the organs involved, the extent and degree of disease. This provides some standardization to the patient's condition. Category P represents parasite dissemination in the liver, category N represents the involvement of adjacent organs, and category M represents distant metastasis. Following this, the patients are staged as I, II, IIIA, IIIB or IV [15].

#### *Imaging Methods*

USG is a first-line imaging technique in suspected cases. CT and MRI are required for complete characterization and preoperative evaluation.

On USG, typical findings include a large hepatic lesion with areas of hyper- and hypoechoogenicity and scattered foci of calcification. Margins are usually irregular. Multiple hyperechoic nodules give rise to hailstorm appearance are sometimes seen. Color Doppler imaging can show vascular/biliary invasion and displacement due to mass effect [15-17].

CT is used for morphological characterization of the lesion. The presence/absence of calcifications can also be excluded. It is also possible to evaluate vascular, biliary or extrahepatic invasion.

Non-contrast images usually reveal an infiltrative mass with irregular margins; attenuation is variable with foci of hyperattenuation (calcium) and hypoattenuation (necrosis, parasitic tissue). No intralésional enhancement is usually seen; however, peripheral fibroinflammatory component may enhance in delayed phase images. Other lesions that need to be differentiated include cholangiocarcinoma, biliary cystadenoma and hepatic metastases [15, 18, 19].

MRI can demonstrate lesion components and depict the biliary and vascular tree involvement in great detail. Imaging findings include the mass with irregular margins and an intermediate to low signal on T1W and low on T2W images. The areas of T2 hyperintensities which correspond to necrotic/cystic change may be seen. Contrast phase images on MRI follow similar pattern as seen on CT, i.e., no contrast uptake in large proportion of mass with subtle peripheral enhancement on gadolinium-enhanced T1 images due to inflammatory fibrofatty parenchyma.

In diffusion weighted imaging, the absence of restricted diffusion differentiates it from neoplastic lesions; however, peripheral restricted diffusion may be seen secondarily due to the abscess formation. Kodama et al. have characterized hepatic lesions into 5 types [20]:

Type 1 - multiple small cysts with no associated solid component (4%);

Type 2 - solid component with multiple small cysts (40%);

Type 3 - solid component surrounding a large pseudocyst with multiple small round cysts (46%);

Type 4 - solid component without cysts (4%);

Type 5 - large cyst without a solid component (6%).

Recently, positron emission tomography-computed tomography (PET-CT) has emerged as a valuable tool in evaluating the metabolic activity of a parasitic lesion and has been quite helpful in evaluating treatment response, since a decrease in (fluorodeoxyglucose) FDG activity following chemotherapy indicates good response. Thus, PET-CT plays an important role in long-term follow-up [17, 21-23].

#### Differential diagnosis

Primary or metastatic hepatic neoplasms can be included in differentials. USG appearance of hailstorm can be mistaken for hemangiomas [17].

On MRI, type 1 lesion can be confused with cystadenoma or localized Caroli's disease. For Type 2 and 3 lesions, cystadenomas, cystadenocarcinoma or peripheral cholangiocarcinoma can be included as differentials; however, these show the absence of calcifications and the presence of contrast enhancement. Type 4 lesions appear solid and include many hepatic malignancies as differentials. Type 5, on the other hand, may be confused with hepatic cyst, hydatid cyst and hepatic abscess [8, 17, 20, 24]. CT findings in the absence of cystic component and calcifications can be confused with cholangiocarcinoma; on the other hand, lesions presenting as a large cystic component may be confused with hydatid cyst, abscess, cystadenoma-adenocarcinoma [8].

Based on the imaging findings in our cases, typical radiological appearance of alveolar hydatid disease can be summarized as an irregular hypoattenuating mass lesion having typical calcifications (can be peripheral, as well as central) with tiny cystic components. No enhancement of the lesion is seen; however, weak peripheral enhancement may be present.

#### Conclusions

Alveolar hydatid disease is a rare condition and offers a diagnostic dilemma on imaging especially in non-endemic regions. It is important to be familiar with its imaging findings, as it plays important role in planning surgical management. In this case series, we have described imaging findings in six cases with the aim their considering in differentials of non-enhancing hypodense hepatic lesions even in non-endemic regions. We believe that the recent surge in the cases of alveolar hydatid disease in Kashmir region of India is due to deforestation, cattle grazing and human settlements coming up near the natural habitat of wild foxes resulting in increased man-animal conflict.

#### References

- Eckert J, Deplazes P. Biological, epidemiological, and clinical aspects of echinococcosis, a zoonosis of increasing concern. *Clin Microbiol Rev.* 2004;17:107-135. doi: 10.1128/CMR.17.1.107-135.2004
- Vuitton DA, Zhou H, Bresson-Hadni S et al. Epidemiology of alveolar echinococcosis with particular reference to China and Europe. *Parasitology.* 2003;127(1):87-107.
- McManus DP, Zhang W, Li J et al. Echinococcosis. *Lancet.* 2003;362(9392):1295-1304. doi: 10.1016/S0140-6736(03)14573-4
- Aikat BK, Bhusurmath SR, Cadarsa M et al. Echinococcus

multilocularis infection in India: first case report proved at autopsy. *Trans R Soc Trop Med Hyg.* 1987;72(6):619-621. doi: https://doi.org/10.1016/0035-9203(78)90015-9

- Bhatia JK, Ravikumar R, Naidu CS et al. Alveolar hydatid disease of the liver: A rare entity in India. *Med J Armed Forces India.* 2016;72(1):126-129. doi: 10.1016/j.mjafi.2015.12.005

- Madhusudhan KS, Srivastava DN, Dash NR et al. Alveolar echinococcosis of liver: a diagnostic problem in a nonendemic area. *Curr Probl Diagn Radiol.* 2015;44(2):221-226. doi: 10.1067/j.cpradiol.2014.08.006.

- Fomda BA, Khan A, Thokar MA et al. Sero-epidemiological survey of human cystic echinococcosis in Kashmir, North India. *PLoS One.* 2015;10(4):e0124813. doi: 10.1371/journal.pone.0124813.

- Kantarci M, Bayraktutan U, Karabulut N et al. Alveolar echinococcosis: spectrum of findings at cross-sectional imaging. *Radiographics.* 2012;32(7):2053-2070. doi: 10.1148/rg.327125708.

- Koroglu M, Akhan O, Gelen MT et al. Complete resolution of an alveolar echinococcosis liver lesion following percutaneous treatment. *Cardiovasc Intervent Radiol.* 2006;29(3):473-478. doi: 10.1007/s00270-005-0017-0

- Gottstein B. Purification and characterization of a specific antigen from *Echinococcus multilocularis*. *Parasite Immunol.* 1985;7(3):201-212. doi: 10.1111/j.1365-3024.1985.tb00070.x

- Gottstein B, Jacquier P, Bresson-Hadni S et al. Improved primary immunodiagnosis of alveolar echinococcosis in humans by an enzyme-linked immunosorbent assay using the Em2plus antigen. *J Clin Microbiol.* 1993;31(2):373-376.

- Ito A, Schantz PM, Wilson JF. Em18, a new serodiagnostic marker for differentiation of active and inactive cases of alveolar hydatid disease. *Am J Trop Med Hyg.* 1995;52(1):41-44. doi: https://doi.org/10.4269/ajtmh.1995.52.41

- Helbig M, Frosch P, Kem P et al. Serological differentiation between cystic and alveolar echinococcosis by use of recombinant larval antigens. *J Clin Microbiol.* 1993;31(12):3211-3215.

- Sarciron EM, Bresson-Hadni S, Mercier M et al. Antibodies against *Echinococcus multilocularis* alkaline phosphatase as markers for the specific diagnosis and the serological monitoring of alveolar echinococcosis. *Parasite Immunol.* 1997;19(2):61-68. doi: 10.1046/j.1365-3024.1997.d01-183.x

- Brunetti E, Kern P, Vuitton DA et al. Expert consensus for the diagnosis and treatment of cystic and alveolar echinococcosis in humans. *Acta Trop.* 2010;114:1-16. doi: 10.1016/j.actatropica.2009.11.001.

- Bartholomot G, Vuitton DA, Harraga S et al. Combined ultrasound and serologic screening for hepatic alveolar echinococcosis in central China. *Am J Trop Med Hyg.* 2002;66(1):23-29. doi: 10.4269/ajtmh.2002.66.23

- Bresson-Hadni S, Delabrousse E, Blagosklonov O et al. Imaging aspects and non-surgical interventional treatment in human alveolar echinococcosis. *Parasitol Int.* 2006;55:267-272. doi: 10.1016/j.parint.2005.11.053

- Reuter S, Nessel K, Kolokythas O et al. Alveolar liver echinococcosis: a comparative study of three imaging techniques. *Infection.* 2001;29(3):119-125. doi: 10.1007/s15010-001-1081-2

- Didier D, Weiler S, Rohmer P et al. Hepatic alveolar echinococcosis: correlative US and CT study. *Radiology.* 1985;154(1):179-186. doi: 10.1148/radiology.154.1.3880602

- Kodama Y, Fujita N, Shimizu T et al. Alveolar echinococcosis: MR findings in the liver. *Radiology.* 2003;228(1):172-177. doi: 10.1148/radiol.2281020323

- Reuter S, Schirmeister H, Kratzer W et al. Pericystic metabolic activity in alveolar echinococcosis: assessment and follow-up by positron emission tomography. *Clin Infect Dis.* 1999;29:1157-1163. doi: 10.1086/313438

- Crouzet J, Manton GA, Thevenot T et al. Personalized management of patients with inoperable alveolar echinococcosis undergoing treatment with albendazole: usefulness of positron-emission-tomography combined with serological and computed tomography follow-up. *Clin Microbiol Infect.* 2010;16(6):788-791. doi: 10.1111/j.1469-0691.2009.02924.x

- Stumpe KD, Renner-Schneider EC, Kuenzle AK et al. F-18-fluorodeoxyglucose (FDG) positron-emission tomography of *Echinococcus multilocularis* liver lesions: prospective evaluation of its value for diagnosis and follow-up during benzimidazole therapy. *Infection.* 2007;35:11-18. doi: 10.1007/s15010-007-6133-9

- Karabulut N. Two other hepatic cystic lesions: alveolar echinococcosis and intraductal papillary mucinous tumor of the bile ducts. *Am J Roentgenol.* 2015;204:610.

Received: 14.01.2020

Revised: 21.03.2020

Accepted: 24.03.2020