

Marcin Jankowski, Jolanta Spużak, Krzysztof Kubiak, Maciej Grzegory, Agnieszka Haloń*, Kamila Glińska-Suchocka, Józef Nicpoń, Vasyl Vlizlo, Igor Maksymovych*****

Department of Internal Diseases with Clinic for Horses, Dogs and Cats, Faculty of Veterinary Medicine, University of Environmental and Life Sciences, pl. Grunwaldzki 47, 50-366 Wrocław, Poland

**Department of Pathomorphology, Medical University, ul. K. Marcinkowskiego 1, 50-368 Wrocław*

*** Institute of the Animal Biology of UAAS, Lviv, Ukraine*

****Department of Clinical Diagnostics, Lviv National University of Veterinary Medicine and Biotechnology, ul. Pekarska 50, 79010 Lviv, Ukraine*

RHINOSCOPY IN DOGS

Key words: *rhinoscopy, dog*

Introduction

Rhinoscopy is a diagnostic method of examining nasal cavities by means of endoscope. It can be divided into anterior rhinoscopy and posterior rhinoscopy. In anterior rhinoscopy the nasal cavities are examined with rigid or flexible endoscopes introduced by the nasal foramens (nostrils), whereas in posterior rhinoscopy the choanae are examined from the side of the throat using an elastic endoscope (1, 2, 5, 6, 8, 9).

The indications for rhinoscopy include: persistent unilateral or bilateral nasal discharge, recurrent nose bleeding, persistent sneezing, the nose area deformation, the nasal stridor, the nasal area tenderness, stertor respiration, suspicion of foreign bodies in nasal cavities and suspicion of neoplastic changes (1, 2, 3, 4, 5, 8, 9, 10).

In anterior rhinoscopy most frequently are used rigid endoscopes of the following parameters: visual angle 0° - 30°, length – up to 50 cm and diameter 2 mm – 5 mm. Flexible endoscopes of the similar parameters are less frequently used in this kind of rhinoscopy. In posterior rhinoscopy only flexible endoscopes of the diameter 6 mm – 10 mm are used. It should be noted that the parameters of the endoscopes employed in rhinoscopy depend on the animal's size and the diameter of the nasal cavities. Qualification of animals for rhinoscopy should be based on: the history, the clinical examination results and the results of additional examinations such as: laboratory blood tests (hematological and biochemical) and an X-ray examination of the nasal cavities (1, 2, 3, 5, 6, 8, 9).

Rhinoscopy is performed under general anaesthesia after a proper dietetic preparation including 24 h fasting and a 6 h break in administration of water directly before the procedure. The nasal cavities endoscopy is conducted in the sternal or lateral position (1, 2, 6, 8, 9, 10).

In rhinoscopy attention should be paid to: the shape of elements forming the structure of the nasal cavities and the area of choanae, the mucosa condition (colour,

moisture, brittleness), the blood vessels picture and the presence of: secretion (colour, consistence, additives), foreign bodies and hypertrophic changes (1, 2, 4, 5, 8, 9).

Task, the aim of the article

The aim of the study was to evaluate usefulness of rhinoscopy in diagnosis of the nasal cavities diseases in dogs.

Material and methods

The study included 29 dogs of different breed and sex, aged 9 month – 13 years, referred to the nasal cavities endoscopy in the Endoscopy Laboratory of the Department of Internal Diseases with Clinic for Horses, Dogs and Cats. Prior to rhinoscopy all the animals underwent the history, clinical examination, laboratory blood tests (hematological tests: RBC, HGB, HCT, WBC, PLT; biochemical tests: AST, ALT, ALP, urea, creatinine) and an X-ray examination of the nasal cavities. In addition, in justified cases also a microbiological (bacteriological and mycological) and histopathological examinations were carried out in the studied animals.

The endoscopy of the nasal cavities was performed after 24 h fasting and 6 h break in administration of water in the left lateral position and under general anaesthesia. Premedication included xylazine with atropine and thiopentale for general anaesthesia.

For examination of the nasal cavities the following endoscopes were used: in anterior rhinoscopy – rigid endoscopes: Olympus A5290A (working length – 30 cm, diameter – 5.5 mm) and Olympus A4672A (working length – 28 cm, diameter – 3 mm) and in posterior rhinoscopy – flexible endoscopes: Super Vision (working length – 60 cm, diameter – 5 mm) and Olympus GIF XQ 20 (working length – 100 cm, diameter – 9.8 mm).

Result of research

The dog referred to rhinoscopy displayed the following clinical signs: the unilateral or bilateral nasal discharge – 20 cases (including: serous – 4 cases, serous-mucous – 2 cases, mucous – 3 cases, purulent – 8 cases and purulent-bloody – 3 cases), difficulties in breathing through the nose – 9 cases, stertor respiration – 6 cases, sneezing – 13 cases, the nose bleeding – 6 cases and nasal stridor – 7 cases. The percentage part of the clinical signs occurring in the dogs referred to rhinoscopy is presented in Fig. 1. The similar clinical signs in the dogs with the nasal cavities diseases were confirmed by other authors (7, 10, 11, 12).

The hematological examination in the dogs referred to rhinoscopy showed an increased leucocyte count in 6 (20.7%) cases. The remaining hematological parameters as well as biochemical parameters were with the physiological norm. The mean, standard deviation and maximum and minimum values of the hematological and biochemical blood parameters are presented in Tab. 1.

The X-ray examination of the nasal cavities did not show any pathological changes in 14 (48.3%) cases. In 15 (51.7%) cases dimness of one or two nasal canals sometimes with blurring of the nasal turbinated bones was observed.

The endoscopy examination of the nasal cavities (anterior and posterior rhinoscopy allowed the diagnosis of: rhinitis – 20 (69.1%) cases, foreign bodies – 5

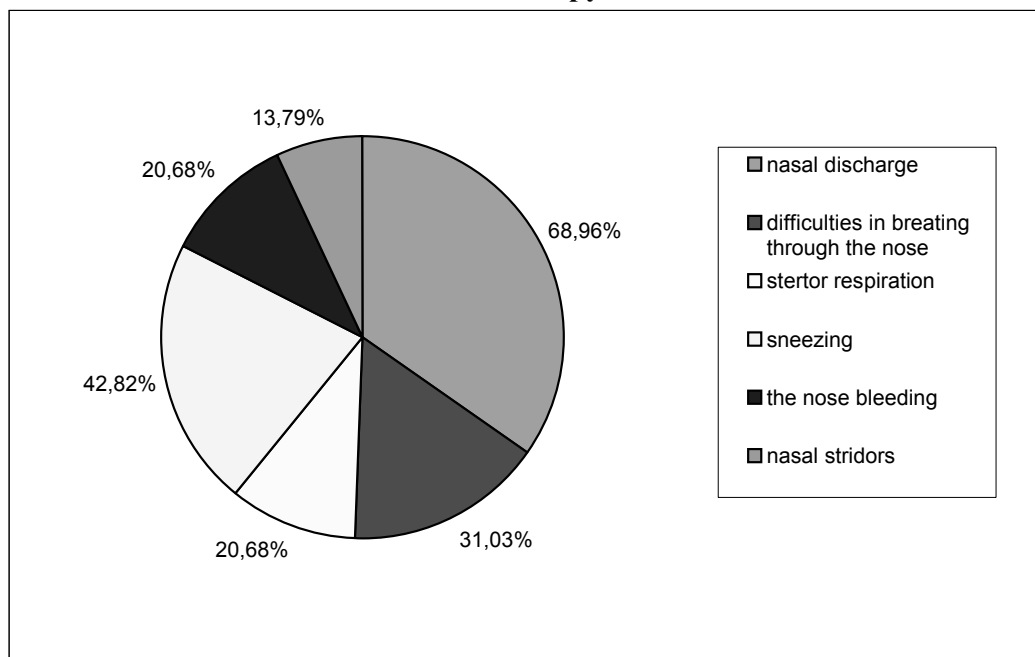
(17.2%) cases (including: grass blades – 4 cases, a fragment of a lignified plant stalk – 1 cases) and neoplastic changes – 4 (13.7%) cases.

The microbiological examination of the nasal cavities smears collected from 13 dogs showed a growth in bacteria: *Escherichia coli*, *Escherichia coli* mucous strain, *Staphylococcus epidermidis*, *Staphylococcus aureus*, *Pasteurella multocida*, *Pseudomonas aeruginosa*, *Streptococcus* sp., *Staphylococcus* sp. *Staphylococcus intermedius* oraz *Moraxella* sp. The similar bacteria in the microbiological examination of the nasal cavities were observed by Meler et al. (7). In the mycological examination only in 1 case a growth of fungi was observed and that was *Aspergillus candidus*.

The histopathological examination of the nasal cavity mucosa bioptates collected from 9 dogs showed: neoplastic changes – 4 cases (including; lymphoma malignum – 1 case, adenocarcinoma – 2 cases and squamous cell carcinoma – 1 case), necrotic – pulurent masses with numerous mycelia – 1 case, chronic massive rhinitis – 3 cases, rhinitis and the nose polyp fragmentum – 1 case.

After both anterior and posterior rhinoscopy in 28 (96.6%) cases no complications occurred. Only in 1 (3.4%) case the removal of a foreign body stick in the nasal cavity mucosa was followed by a massive bleeding which fortunately was stopped.

Fig. 1. Percentage part of separate clinical signs occurring in dogs referred to rhinoscopy



Tab. 1.

The mean, standard deviation, maximum and minimum value of hematological and biochemical blood parameters in dogs referred to rhinoscopy.

Parameter	Unit	Mean	Standard deviation	Minimum value	Maximum value	Physiological norm
RBC	T/l	7.10	± 0.79	5.86	8.5	5.5–8.9
HGB	mmol/l	9.38	± 1.07	7.6	11.2	7.4-11.8
HCT	l/l	0.470	± 0.047	0.382	0.55	0.37-0.55
WBC	G/l	12.52	± 4.75	6.4	25.8	6-15
PLT	G/l	305.72	± 106.76	150.0	489.0	150-500
AST	U/l	44.37	± 17.71	21.0	85.0	<90
ALT	U/l	69.08	± 85.23	11.0	98.3	<100
ALP	U/l	55.91	± 26.39	12.0	95.0	<100
Mocznik	mmol/l	5.90	± 1.65	3.3	8.62	3.3-8.9
Kreatynina	µmol/l	113.94	± 21.76	88.4	150.0	88-159

Conclusion

Based on the conducted study it was found that rhinoscopy is a safe and very useful technique in diagnosis of the nasal cavities diseases in dogs. Moreover, in the case of foreign bodies in the nasal cavities rhinoscopy may have therapeutical character and in the case of hypertrophic changes it allows precise collection of bioplates for a histopathological examination.

Reference

1. Elie M., Sabo M.: Basics in canine and feline rhinoscopy. Clin. Tech. Small Anim. Pract. 2006, 21, 60 - 63.
2. Fischer S, Ballauf B, Kraft W.: Rhinoscopy in dogs and cats. Tierarztl. Prax. 1992, 20, 621-627.
3. Harcourt-Brown N.: Rhinoscopy in the dog 1. Anatomy and techniques. Pract. 2006, 28, 170-175.
4. Harcourt-Brown N.: Rhinoscopy in the dog 2. Conditions associated with chronic nasal discharge. Pract. 2006, 28, 238-246.
5. McCarthy T.C., McDermaid S.L.: Rhinoscopy. Vet. Clin. North Am. Small Anim. Pract. 1990, 20, 1265-1290.
6. McKiernan B.: Sneezing and Snorting. What Should I Do? 26th Congress of the World Small Animal Veterinary Association, 8 - 11 August 2001, Vancouver, British Columbia, Canada.
7. Meler E., Dunn M., Lecuyer M.: A retrospective study of canine persistent nasal disease: 80 cases (1998 – 2003). Can. Vet. J. 2008, 49, 71 – 76.
8. Nicpoń J., Kubiak K.: badanie endoskopowe psów i kotów. AWA, 2000, Wrocław.
9. Tams T.R.: Small Animal Endoscopy. C.V. Mosby Company, 1990, St. Louis.

10. Venker-van Haagen A.J.: Nasal Disease and Rhinoscopy; Fungal Disease/Neoplasia. 30th World Congress of the World Small Animal Veterinary Association, 11 – 14 May 2005, Mexico City, Mexico.
11. Windsor R.C., Johnson L.R.: canine chronic inflammatory rhinitis. Clin. Tech. Small Anim. Pract. 2006, 21, 76 – 81.
12. Windsor R.C., Johnson L.R., Herrgesell E.J., DeCook H.E.: Idiopathic lymphoplasmacytic rhinitis in dog: 37 cases (1997 – 2002). J. Am. Vet. Med. Assoc. 2004, 224, 1952 – 1957.

Summary

Jankowski M., Spużak J., Kubiak K., Grzegory M., Haloń A., Glińska-Suchocka K. Nicpoń J., Vlizlo V., Maksymovych I.

RHINOSCOPY IN DOGS

Rhinoscopy is a diagnostic method of examining nasal cavities by means of endoscope. It can be divided into anterior rhinoscopy and posterior rhinoscopy. The aim of the study was to evaluate usefulness of rhinoscopy in diagnosis of the nasal cavities diseases in dogs. The study included 29 dogs of different breed and sex, aged 9 month – 13 years, referred to the nasal cavities endoscopy. The endoscopy examination of the nasal cavities (anterior and posterior rhinoscopy allowed the diagnosis of: rhinitis – 20 cases, foreign bodies – 5 cases (including: grass blades – 4 cases, a fragment of a lignified plant stalk – 1 cases) and neoplastic changes – 4 cases.

Based on the conducted study it was found that rhinoscopy is a safe and very useful technique in diagnosis of the nasal cavities diseases in dogs. Moreover, in the case of foreign bodies in the nasal cavities rhinoscopy may have therapeutical character and in the case of hypertrophic changes it allows precise collection of biotates for a histopathological examination.

Стаття надійшла до редакції 24.09.2010