

УДК 618.3:616.135-136-08-031.84

**B. Cherpak, I. Davydova, I. Ditkivskyy, N. Yaschuk,  
B. Batsak, V. Lazoryshynets**

## **A Case of Endovascular Repair of Mid-Aortic Syndrome Diagnosed During Pregnancy**

SI «National Institute for Cardiovascular Surgery named after M.M. Amosov», Kiev, Ukraine

PERINATOLOGIYA I PEDIATRIYA. 2016.3(67):10-14; doi 10.15574/PP.2016.67.10

The mid-aortic syndrome is a clinical condition generated by segmental narrowing of the abdominal or descending thoracic aorta. It might be either a congenital abnormality in the development of aorta or one of several acquired conditions such as infection, obliterative panarteritis, neurofibromatosis, retroperitoneal fibrosis, fibromuscular dysplasia, mucopolysaccharidosis and Takayasu's arteritis. We are presenting a case of 17-years old female with life threatening hypertension during the onset of pregnancy and unrecognized before the gestation middle aortic syndrome. Because of rarity of this syndrome, only ridiculous evidence exists with regard to the treatment. Single cases of surgery and interventional treatment with stent-graft placement have been reported, as well as good outcomes with only medical management. Unfortunately, the arterial hypertension in our patient was resistant on 3-drug antihypertensive regimen. She has successful endovascular mid-aortic syndrome repaired with CP covered stent on the 24-th week of pregnancy. The blood pressure decreased from 220/110 mmHg to 140/90 mmHg after the procedure. 3 months later the patient experienced the spontaneous vaginal delivery and gave birth to a healthy male newborn.

**Key words:** mid-aortic syndrome, pregnancy, endovascular stent graft placement.

### **Introduction**

Coarctation of the abdominal aorta (CoA), or mid-aortic syndrome, is a rare vascular abnormality often producing life threatening arterial hypertension. Coarctation of the aorta accounts for approximately 11% of cases seen in the GUCH (grown-up with congenital heart disease) clinics and if not timely relieved is responsible for the persistent hypertension (30% at the age of 10 years; 66% at 40 years), premature coronary artery disease (25%) and severe berry aneurysms (2–3%). This arterial hypertension is usually resistant to all groups of the antihypertensive medications. Also, the hypertension is a frequent medical complication during pregnancy (normal pregnancy – preeclampsia 11% in population). Unrecognized causes of the pre-existing hypertension occasionally become apparent only in pregnancy. Management of hypertension during pregnancy is challenging due to the fetal toxic impact of some drugs, namely ACE inhibitors and ABRs. Moreover, the females with aortic coarctation contemplating pregnancy should have repair prior to pregnancy. Management of hypertension in the uncorrected pregnant patient may be problematic, because of too low pressure below the coarctation site may result in compromising of fetus, antenatal fetal death or abortion. The risk of aortic dissection or aneurysm rupture during pregnancy is low, but the maternal mortality risks are significantly higher if one of these occurs. To our best knowledge no one case of middle aortic syndrome repair during pregnancy has been described till nowadays. According to ESC guidelines on the management of cardiovascular diseases during pregnancy the percutaneous intervention for undiagnosed coarctation or re-CoA is possible during pregnancy, but it is associated with a higher risk of aortic dissection than in the non-pregnant patient and should only be performed if severe hypertension persists despite maximal medical therapy and there is the evidence of maternal or fetal compromise [3]. We are presenting a case of the endovascular treatment of mid-aortic syndrome with a CP covered stent during pregnancy, because of the uncontrollable hypertension.

### **Case presentation**

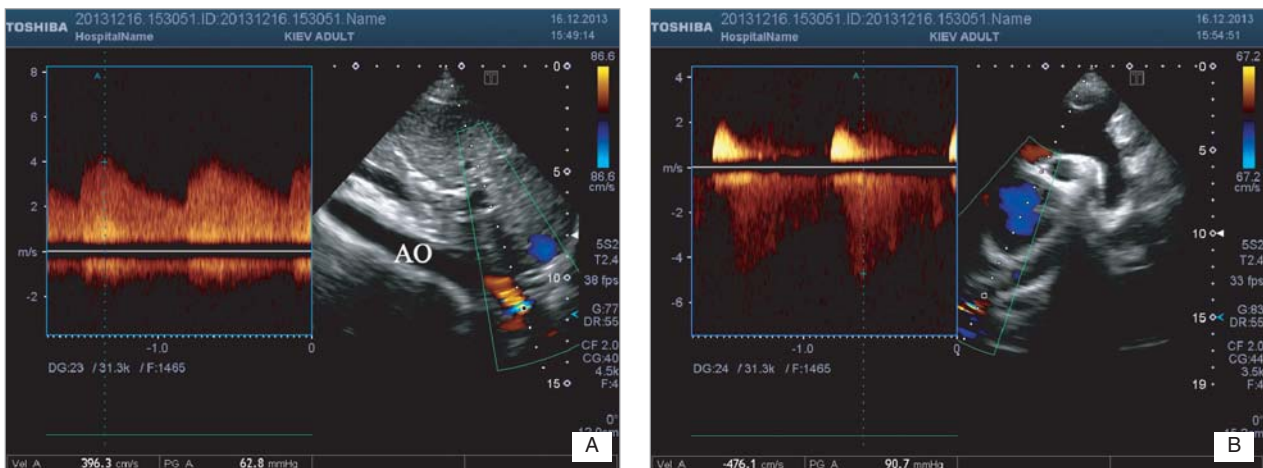
A 17-years old woman admitted in her 24-th week of gestation with uncontrollable hypertension. On the physical examination the blood pressure was 220/110 mmHg on her arms. The blood pressure was resistant to three drug antihy-

pertensive regimen: calcium channel blockers,  $\beta$ -blockers and thiazide diuretics. Also she had weak pulse on her legs. The lower limb pressure was unrecordable by the cuff measurements. The rest of the physical examinations were unremarkable. Coarctation of aorta was suspected.

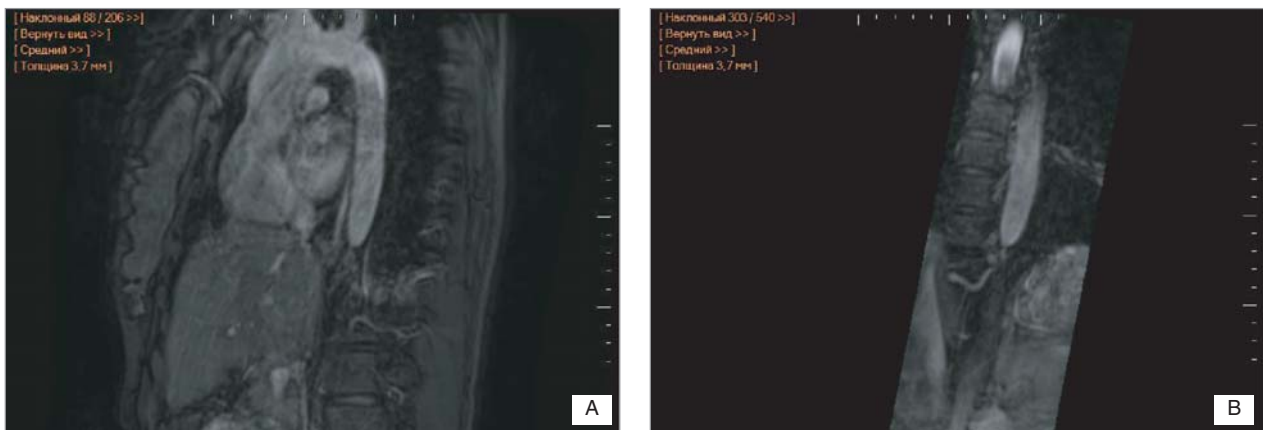Echocardiography showed mild left ventricular hypertrophy, the abdominal aortic flow was compatible with coarctation. During precise ECHO examination the coarctation of descending thoracic aorta above the diaphragm level was found with the peak gradient on it 90 mmHg (Figure 1). Because of pregnancy the patient was referred to MRI in order to get a better image and avoided the x-ray exposure. We used nonenhanced sequences with ECG-gated partial Fourier fast spin-echo, balanced steady-state free precession (SSFP). Noncontrast SSFP imaging enables rapid visualization of narrowing in «single shot» mode and a more detailed evaluation in any plane. The high signal-to-noise and contrast-to-noise ratio (due to cardiac and respiratory gating) and very quick sequences render SSFP useful for the pregnant patients. This investigation showed long segmental narrowing of descending thoracic aorta right above the diaphragm level with a pinhole orifice of about 2 mm in diameter (Figure 2).

It was decided to perform the percutaneous intervention for this patient because of the uncontrollable hypertension and major risk of the aortic dissection and possible rupture of the cerebral aneurysm. In the presence of a multidisciplinary team of an interventional cardiologist, cardiovascular surgeon, and obstetrician, specialized for cardio-vascular problems in pregnancy, neonatologist and anesthesiologist.

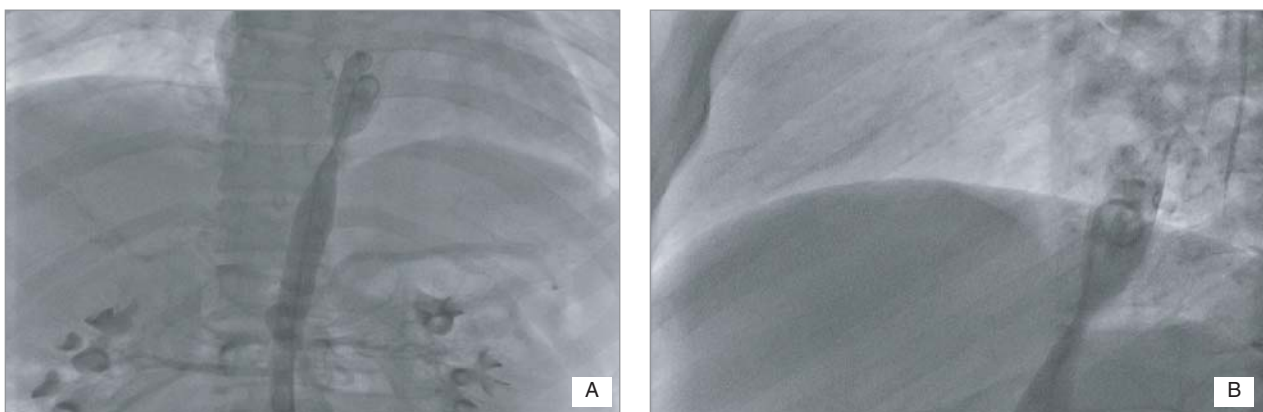
The procedure was performed under the local anesthesia. The right femoral artery was punctured. During all procedure the fetus was protected with a lead cover to negate the radiation exposure. Heparin was administered intravenously, at a dose of 100 IU/kg. 6 Fr multi-purpose catheter (Cordis, Jonson&Jonson, USA) was used to cross the stenosis in the aorta with the help of 0,035" glide wire (Terumo Company, Japan), which was advanced in a stable position across the stenosis and located in the ascending aorta. The hemodynamic measurements were recorded with the aortic pressures above and below the narrowing. The obtained gradient was 110 mmHg. The concentric narrowing of thoracic aorta above the diaphragm level was shown by the biplane aortography in the antero-posterior and lateral view (Figure 3).



**Fig. 1. A.** Subxiphoid view. Abdominal aortic flow was compatible with coarctation. Turbulence of the flow in descending thoracic aorta just above the diaphragm level (coarctation). **B.** High parasternal short axis view. Turbulence of the flow in descending thoracic aorta just above the diaphragm level (coarctation) with the peak gradient on it 90 mmHg



**Fig. 2.** Rapid non-contrast MRA with cardiac and respiratory gating showed long segmental narrowing of descending thoracic aorta right above the diaphragm level, it measures about 2 mm in diameter



**Fig. 3.** Aortography in the antero-posterior (A) and lateral (B) projections. Coarctation of descending thoracic aorta just above the diaphragm level (the narrowest diameter is 2 mm)

There was also no evidence of the abdominal aortic branches stenosis due to this investigation. Measurements of the anatomic details were performed. The diameter of the aorta above and below the stenotic segment was 14 mm, the narrowest lesion was 2 mm. The stiff exchange length 260 mm 0.035" Amplatz guidewire (Cordis, Jonson&Jonson, USA) was positioned across the stenosis with a soft J-curve tip in

the ascending aorta. The appropriate CP covered 8Z34 stent (NuMED Canada Inc.) was mounted on the 14x40 mm balloon-in-balloon (BiB) catheter (NuMED Canada Inc.) in a position related to the markers on the balloon catheters. 10 Fr Mullins sheath (Cook Medical, USA) with a radio-opaque marker at its tip was placed across the stenosis with the marker above the stenosis. The stent/balloon assembly was

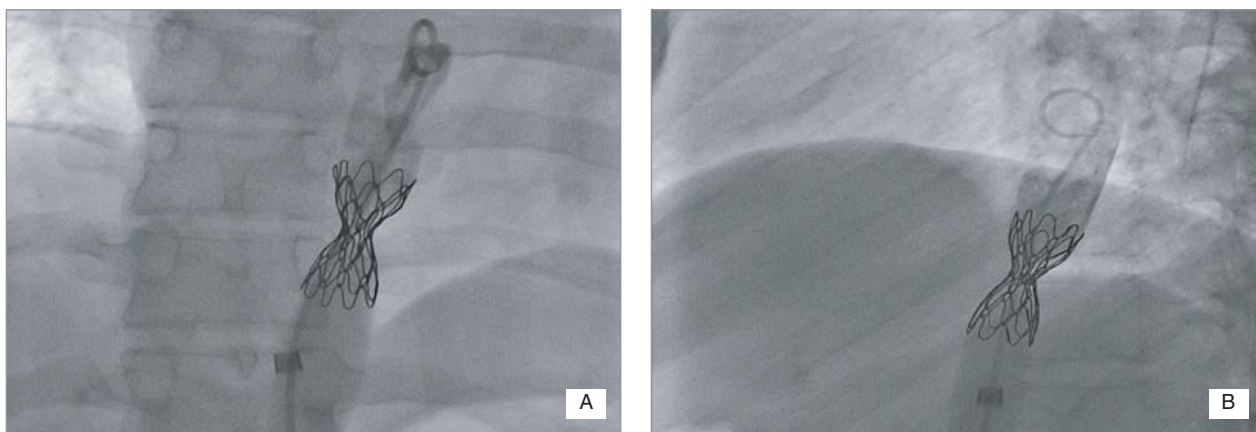


Fig. 4. First aortography in the antero-posterior (A) and lateral (B) projections showed no changes after the stent-graft placement on BiB

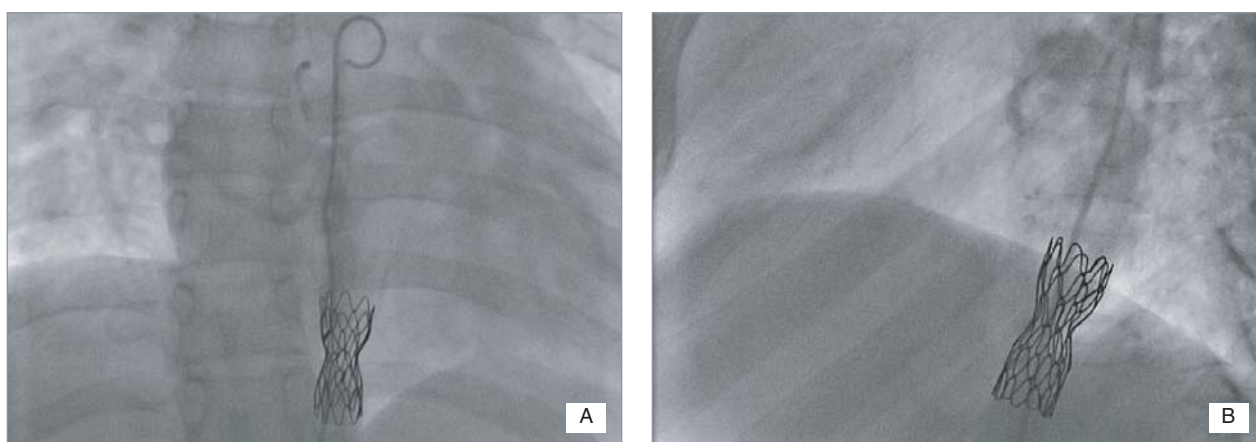


Fig. 5. Aortography in the antero-posterior (A) and lateral (B) projections after angioplasty with Opta-Pro and Atlas balloons. The narrowing has been relieved

advanced through the sheath under fluoroscopic guidance and placed across the stenosis. The accurate positioning of the stent was checked with the hand injections of contrast through the side-port of the sheath. Inner and outer balloon inflation was subsequently performed up to 6 atm. without sufficient stent opening on the stenotic segment of the vessel. The Multitrack catheter (B. Braun Interventional Systems Inc., USA) was inserted over the exchange wire into the aorta above the dilated area and aortography was repeated in the same projection as prior to the stent implantation. The first aortography showed no changes after the stent-graft placement (Figure 4). Also, there was almost no pressure gradient change across the stenosis. It was decided to use the high pressure balloons. We repeated angioplasty with OptaPro 9x20 mm (Cordis, Jonson&Jonson, USA) and Atlas 12x20 mm (Bard Peripheral Vascular Inc. USA) with the pressure of 10 and 16 atm. consequently, repeating the aortography after each attempt. The final aortography showed a satisfactory result on the angioplasty site (Figure 5). Despite the slight recoil of aorta the gradient across stenosis dropped to 25 mmHg. The systolic blood pressure decreased to 140/90 mmHg. The decision was made to stop the procedure in order to avoid the high risk of aortic wall injury. The post procedural ECHO showed normal abdominal aortic flow (Figure 6).

After the procedure the patient's blood pressure never again increased above 140/90 mmHg. According to the guidelines on arterial hypertension management during pregnancy, the aggressive treatment is mandatory when the blood pressure is higher than 170/110 mmHg [4]. So our patient

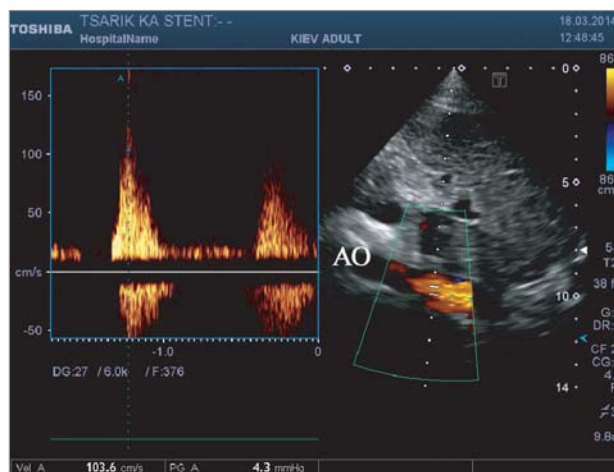


Fig. 6. Subxiphoid view. Postprocedural ECHO showed normal abdominal aortic flow

had no necessity of any antihypertensive treatment, but the attention was paid for the early detection of any symptoms of the superimposed preeclampsia. The spontaneous vaginal delivery under the epidural anesthesia occurred in 39 weeks of pregnancy, a healthy male newborn 2700 g, 50 cm, 7–8 Apgar score was born. There was no evidence of any cardiovascular complication during the delivery period. Active management of the III period of labour was implemented, the early postnatal period was physiological. The newborn and

mother were discharged on the 7 day of the postnatal period. There was no evidence of any congenital heart diseases in the newborn by means of EchoCG performed on the 4 day of life.

#### Discussion

The mid-aortic syndrome is a life threatening condition because of possible complications caused by the upper limb arterial hypertension. Moreover, the native severe coarctation is a condition in which pregnancy risk — WHO IV (World Health Organization), what means — pregnancy contraindicated [3]. There was just a few cases of the mid-aortic syndrome diagnosed during pregnancy reported [1,2,5,6]. The secondary hypertension during pregnancy is present in 5 to 10% of cases and must be considered in presence of drug resistance [5]. Treatment of the arterial hypertension is mandatory when the blood pressure is higher than 170/90 mmHg [4]. Although, we should bear in mind, that the aggressive treatment of arterial hypertension must be avoided in the patient with coarctation of aorta to prevent the placental hypoperfusion [3]. All antihypertensive drugs are assumed to cross the placenta and reach the fetal circulation. However, none of antihypertensive agents in routine use have been documented to be teratogenic, butrgvgr ACE inhibitors and ARBs are fetotoxic. So, the mentioned medication should be avoided in the pregnant woman [4].

Depending on the experience of the units different treatment strategies are used in the management of mid-aortic syndrome. The surgery is widely accepted especially in older patients and in the complex mid-aortic syndrome associated with the renal and visceral arterial stenosis. The type of surgery may involve a thoracoabdominal to infrarenal aortic bypass with the renal artery re-implantation, splenorenal

bypass, aortorenal bypass, and autotransplantation. Experience over the last decade has shown that this pathology can be treated with the percutaneous techniques, such as balloon angioplasty or stent implantation, depending on anatomy and age of the patient [1,8].

The largest study with experience of treatment of the mid-aortic syndrome over last 30 years belongs to Boston Children's Hospital and Harvard Medical School [8]. This study involved 53 patients. 35 pts underwent the invasive management, of them 21 pts had the percutaneous interventions, 5 pts — surgical techniques, 9 pts — both. According to this study the percutaneous interventions were very successful in decreasing the gradient across stenosis. However, freedom from reintervention at 1 and 5 year was 58% and 33% respectively after the percutaneous techniques, and it was longer after the surgery — 83% and 72% respectively.

But, to our best knowledge no one case of the mid-aortic syndrome repair during pregnancy has been described. There are some sporadic cases of the mid-aortic syndrome diagnosed during pregnancy, which was successfully managed just with medication [1,2]. As was previously stated, the percutaneous intervention for undiagnosed coarctation or re-CoA is possible during pregnancy, but it is associated with a higher risk of aortic dissection than outside the pregnancy and should only be performed if severe hypertension persists despite maximal medical therapy and there is a maternal or fetal compromise [3].

The represented case gives us a clear message: the mid-aortic syndrome could be successfully and safely managed with the percutaneous stent-graft placement during pregnancy when the benefits exceed the potential risk.

#### REFERENCES

- Willner J.B. Successful pregnancy after aortic stent-graft in a patient with middle aortic syndrome / J.B. Willner, T.J. Hatfield, A.B. Hameed // *American journal of obstetrics and gynecology* (Impact Factor: 3.28). — 2009, March. — Vol. 200(6). — P. e4—5. doi:10.1016/j.ajog.2008.11.039.
- Hajsadeghi Sh. Suprarenal abdominal aortic coarctation diagnosed during pregnancy / Sh. Hajsadeghi, M. Chitsazan, H. Rahbar // *Iranian Cardiovascular Research Journal*. — 2010. — Vol.4, No.4.
- ESC Guidelines on the management of cardiovascular diseases during pregnancy / V. Regitz-Zagrosek, C. Blomstrom Lundqvist, C. Borghi, R. Cifkova, R. Ferreira, J.-M. Foidart†, J.S.R. Gibbs, Ch. Gohlke-Baerwolf, B. Gorenek, B. lung, M. Kirby, A. H.E.M. Maas, J. Morais, P. Nihoyannopoulos, P.G. Pieper, P. Presbitero, J.W. Roos-Hesselink, M. Schaufelberger, U. Seeland, L. Torracca // *European Heart Journal*. 2011. — Vol. 32. — P. 3147—3197.
- James P.R. Management of hypertension before, during and after pregnancy / P.R. James, C. Nelson // *Heart*. 2004, Dec. — Vol. 90(12). P. 1499—1504.
- Stone S. A case of congenital mid-aortic syndrome in pregnancy / S. Stone, D. Beattie, M.C. Jolly // *Journal of Human Hypertension*. 2009. — Vol. 23. — P. 143—145. doi 10.1038/jhh.2008.118; published online 18 September 2008.
- Nimit C. Shah, MBBS, MRCP. A young hypertensive woman with a rare diagnosis of middle aortic syndrome // *The journal of clinical hypertension*. — 2008, Oct. — Vol. 10, No 10.
- Sievt H. Percutaneous Interventions for Congenital Heart Disease / H. Sievt, Sh.A. Qureshi, N. Wilson, Z.M. Hijazi // *Informa UK Ltd*. — 2007.
- Porras D. Midaortic syndrome: 30 years of experience with medical, endovascular and surgical management / D. Porras, D.R. Stein // *Pediatric nephrology*. — 2013, Oct. — Vol. 28(10). — P. 2023—33. doi 10.1007/s00467-013-2514-8. Epub 2013 Jun 18.
- Endovascular surgery by means of a Talent endoprosthesis implant in adult patients with thoracic aorta coarctation // *J. Cardiovasc. Surg. (Torino)*. — 2008, Aug. — Vol. 49(4). — P. 483—7.
- Fink-Josephi G. Coarctation of the aorta: outcome of pregnancy / G. Fink-Josephi, S. Gutierrez-Vogel, L.M. Hurtado-Lopez, C. Calderon // *J. Am. Coll. Cardiol*. — 2001, Nov. — Мщдю 15, No 38(6). — P. 1728—33.
- Beauchesne L.M. The adult patient with native coarctation of the aorta: balloon angioplasty or primary stenting? / L.M. Beauchesne, H.M. Connolly, N.M. Ammass, C.A. Warnes // *Heart*. — 2003, Jan. — Vol. 89(1). — P. 77—83.

**Эндоваскулярное лечение среднего аортального синдрома во время беременности****Б. Черпак, Ю. Давыдова, И. Дитковский, Н. Ящук, Б. Бацак, В. Лазоришинец**

ГУ «Национальный институт сердечно-сосудистой хирургии имени М.М. Амосова», Киев, Украина

Средний аортальный синдром представляет собой клиническое состояние, возникающее вследствие сегментарного сужения брюшной или нисходящей грудной аорты. Это может быть как врожденной аномалией развития аорты, так и следствием одной из приобретенных заболеваний, таких как: инфекции, облитерирующий панартериит, нейрофиброматоз, забрюшинный фиброз, фиброзно-мышечная дисплазия, мукополисахаридоз и синдром Такаюсу. В статье представлен случай 17-летней пациентки с опасной для жизни артериальной гипертензией во время наступления беременности и нераспознанным до беременности средним аортальным синдромом. Из-за редкости данного синдрома, очень сложно определить и найти правильный подход к его лечению. В статье указаны отдельные случаи хирургии и интервенционной терапии с установкой стент-графта, а также отмечены положительные результаты безоперационного ведения болезни. К сожалению, артериальная гипертензия у нашей пациентки была устойчива к трехпрепаратному антигипертензивному лечению. Однако у пациентки было отмечено значительное улучшение эндоваскулярного среднего аортального синдрома после установки искусственного имплантата CP на 24-й неделе беременности. После проведенной процедуры артериальное давление снизилось с 220/110 мм рт.ст. до 140/90 мм рт.ст. Через 3 месяца пациентка самостоятельно родила здорового мальчика.

**Ключевые слова:** синдром среднего аортального синдрома, беременность, установка эндоваскулярного стент-графта.**Ендоваскулярне лікування середнього аортального синдрому під час вагітності****Б. Черпак, Ю. Давыдова, І. Дитковський, Н. Ящук, Б. Бацак, В. Лазоришинець**

ДУ «Національний інститут серцево-судинної хірургії імені М.М. Амосова», Київ, Україна

Середній аортальний синдром являє собою клінічний стан, який виникає внаслідок сегментарного звуження черевної або нижньої грудної аорти. Це може бути як вродженою аномалією розвитку аорти, так і наслідком одного з набутих захворювань, таких як: інфекції, що облітерують панартеріїт, нейрофіброматоз, зачеревний фіброз, фіброзно-м'язова дисплазія, мукополісахаридоз і синдром Такаюсу. В статті представлений випадок 17-річної пацієнтки з небезпечною для життя артеріальною гіпертензією під час настання вагітності та нерозпізнаним до вагітності середнім аортальним синдромом. Через рідкість даного синдрому, дуже складно визначити та знайти правильний підхід до його лікування. У статті зазначені випадки хірургії та інтервенційної терапії з установкою стент-графта, а також відмічені позитивні результати безопераційного ведення хвороби. Нажаль, артеріальна гіпертензія у нашої пацієнтки була стійка до трьохпрепаратного антигіпертензивного лікування. Однак у пацієнтки було відмічено значне покращення ендоваскулярного середнього аортального синдрому після встановлення штучного імплантату CP на 24-му тижні вагітності. Після проведенної процедури артеріальний тиск знизився з 220/110 мм рт.ст. до 140/90 мм рт.ст. Через 3 місяці пацієнтка самостійно народила здорового хлопчика.

**Ключеві слова:** синдром середнього аортального синдрому, вагітність, встановлення ендоваскулярного стент-графта.**Сведения об авторах:****Черпак Богдан Владимирович** — детский эндоваскулярный хирург ГУ «Национальный институт сердечно-сосудистой хирургии имени М.М. Амосова».

Адрес: г. Киев, ул. Н. Амосова, 6; тел. (044) 275-10-04.

**Давыдова Юлия Владимировна** — д.мед.н., магистр государственного управления, зав. акушерским отделением экстрагенитальной патологии беременных и постнатальной реабилитации ГУ «Институт педиатрии, акушерства и гинекологии НАМН Украины». Адрес: г. Киев, ул. П. Майбороды, 8; тел. (044) 484-18-71.**Дитковский Игорь Александрович** — детский эндоваскулярный хирург ГУ «Национальный институт сердечно-сосудистой хирургии имени М.М. Амосова».

Адрес: г. Киев, ул. Н. Амосова, 6; тел. (044) 275-10-04.

**Ящук Наталья Сергеевна** — эндоваскулярная хирургия, анестезиология, эхокардиография ГУ «Национальный институт сердечно-сосудистой хирургии имени М.М. Амосова». Адрес: г. Киев, ул. Н. Амосова, 6; тел. (044) 275-10-04.**Бацак Богдан Вадимович** — ГУ «Национальный институт сердечно-сосудистой хирургии имени М.М. Амосова». Адрес: г. Киев, ул. Н. Амосова, 6; тел. (044) 275-10-04.**Лазоришинец Василий Васильевич** — член-кор. НАМН Украины, д.мед.н., директор ГУ «НИССХ им. Н.М. Амосова НАМН Украины».

Адрес: г. Киев, ул. Н. Амосова, 6; тел. (044) 275-42-33.

Статья поступила в редакцию 24.08.2016 г.