

# Clinical aspects of tooth autotransplantation and post-endodontic restoration of autotransplanted tooth: case-based literature review

Igor Noenko<sup>A, C, E, F</sup>

DMD, Department of Dentistry, Shupyk National Medical Academy of Postgraduate Education, Kyiv, Ukraine

ORCID ID: 0000-0002-0644-2702

Kostyantyn Kostura<sup>C, D</sup>

DMD, Private practice, Kyiv, Ukraine

ORCID ID: 0000-0003-3348-5713

Olexander Khodakov<sup>B</sup>

DMD, Private practice, Kyiv, Ukraine

ORCID ID: 0000-0002-5288-4763

Corresponding author. Igor Noenko, Department of Dentistry, Shupyk National Medical Academy of Postgraduate Education,

Novopolyova str., 36, of. 1, Kyiv, 03061 Ukraine

E-mail address: nickmess1@gmail.com

A – research concept and design; B – collection and/or assembly of data; C – data analysis and interpretation; D – writing the article; E – critical revision of the article; F – final approval of article

## Article Info

### Artical History:

Paper recieved 15 June 2022

Accepted 4 July 2022

Available online 1 October 2022

### Keywords:

tooth replantation,  
transplantation, endodontic,  
dental restoration, review

<https://doi.org/10.56569/UDJ.1.1.2022.27-36>  
2786-6572/© 2022 The Author(s).

Published by UDJ on behalf of Ukrainian  
public scientific society Continuing  
Dental Education. This is an open access  
article under the CC BY license (<http://creativecommons.org/licenses/by/4.0/>).

## Abstract

**Introduction.** Tooth autotransplantation allows to maintain a vital status of periodontal ligament, which supports the preservation of the alveolar bone volume, better conservation of the interdental papilla and the possibility of dental movement through orthodontic forces. It has been shown that longevity and prognosis of autotransplanted teeth are comparable with those of dental implants.

**Objective.** To discuss major practically-oriented aspects regarding tooth autotransplantation operation including further post-endodontic restoration based on presented clinical case.

**Materials and Methods.** A bibliographic search was conducted in April 2022 by the using MESH terms equivalent to the keywords “tooth” and “autotransplantation” within the Cochrane Library and PubMed database with the aim to identify publications related with practical aspects of tooth autotransplantation presented in clinical case. Data extraction during content-analysis of selected publications was provided selectively in terms to represent the most practically valuable information regarding tooth autotransplantation operation, principles of tooth autotransplantation surgery and further post-endodontic restoration of autotransplanted tooth taking into account aspects highlighted in present clinical case.

**Results.** Due to the provided literature review it was highlighted that success rate of tooth autotransplantation is highly influenced by such factors as the stage of root development, morphology of the tooth, selected surgical procedure, time of extraoral exposure of donor tooth, shape of the recipient socket, vascularity of the recipient site, and the vitality of the periodontal ligament cells, impact of which was considered during presented clinical case.

**Conclusions.** Present clinical case report with accompanied literature review arguments the clinical perspective of tooth autotransplantation procedure as valuable treatment option, and highlights major practically-oriented aspects regarding tooth autotransplantation operation including further post-endodontic restoration of donor tooth. Synergy of tooth autotransplantation and post-endodontic restoration protocols in the hands of an experienced doctor who is ready to carefully follow the scientific evidence-based protocol associated with successful outcome of provided treatment.

## Introduction

Tooth loss remains a common health problem, despite all the efforts targeted at the preservation and improvement of dental health provided by the international health programs and government prevention measures [1]. According to the National Institute of Dental and Craniofacial Research, adults aged 20-64 years had an average loss of 7,08 teeth [1]. Nevertheless, it should be kept in mind that such information applies to the United States of America residents, who due to the economic and social positions are mainly able to

receive qualitative dental care [1]. Of course, tooth loss reflects not only dental disease, but rather several aspects, such as interaction between patients and dentist, the availability and accessibility of dental services, and the prevailing philosophies of dental care [1].

The loss of even one tooth can lead to certain functional, aesthetic and even psychological problems. Today, the most popular ways for epy restoration of the lost teeth are either implant-borne prosthetics, or tooth-borne removable and fixed partial dentures. However, there also is less popular and less known option called tooth autotransplantation, which is a promising alternative, especially

among young patients, where the treatments mentioned above may not be suitable or cannot be performed due to specific reasons [2]. Also, autotransplantation can be performed in growing patients with a high success rate, unlike current implantology techniques. It also allows to maintain a vital periodontal ligament (PDL), which supports the preservation of the alveolar bone volume, better conservation of the interdental papilla and the possibility of dental movement through orthodontic forces [3]. It has been shown that longevity and prognosis of autotransplanted teeth are comparable with those of dental implants [4]. After all, autotransplantation still leaves room for implantation option in the future, moreover a successful autotransplantation allows to preserve bone tissue for further intraosseous fixture placement.

Tooth autotransplantation is the repositioning of an erupted, partially erupted, or impacted autologous tooth from one donor site to another recipient site within the same individual. Recipient site could be presented in the form of a previous extraction site, a surgically prepared socket, or the site of a congenitally missing tooth [5]. The most common donor teeth used in clinical practice are impacted or semi-impacted third molars, while premolars, impacted canines and supernumerary teeth are used for autotransplantation much less often. Both maxillary and mandibular teeth can be successfully used as donor teeth, and teeth could also be successfully autotransplanted within mandibular and maxillary sites. Mandibular donor teeth appear to exhibit the same cumulative survival rate as maxillary donor teeth. Usually literature describes following reasons for tooth extraction at the recipient site: due to trauma, conditions which make restoration impossible, endodontic treatment has failed or tooth has fractured. A success rate of 89.68% and a survival rate of 98% (persistence of the transplanted tooth, with the need for additional procedures) have been published for the open apex autotransplanted teeth, while autotransplanted teeth with complete root development characterized with 80% success and 95% survival [6].

### Objective

To discuss major practically-oriented aspects regarding tooth autotransplantation operation including its further post-endodontic restoration based on presented clinical case.

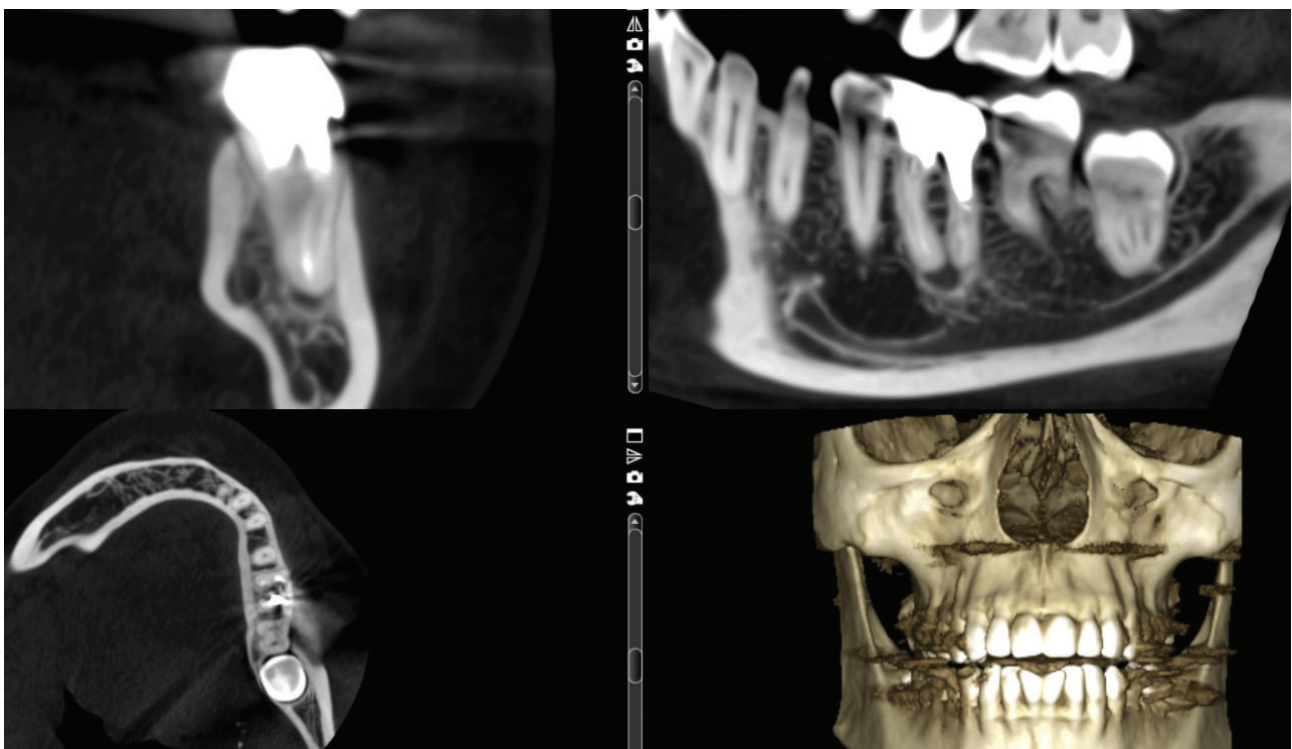
### Materials and Methods

#### Literature review

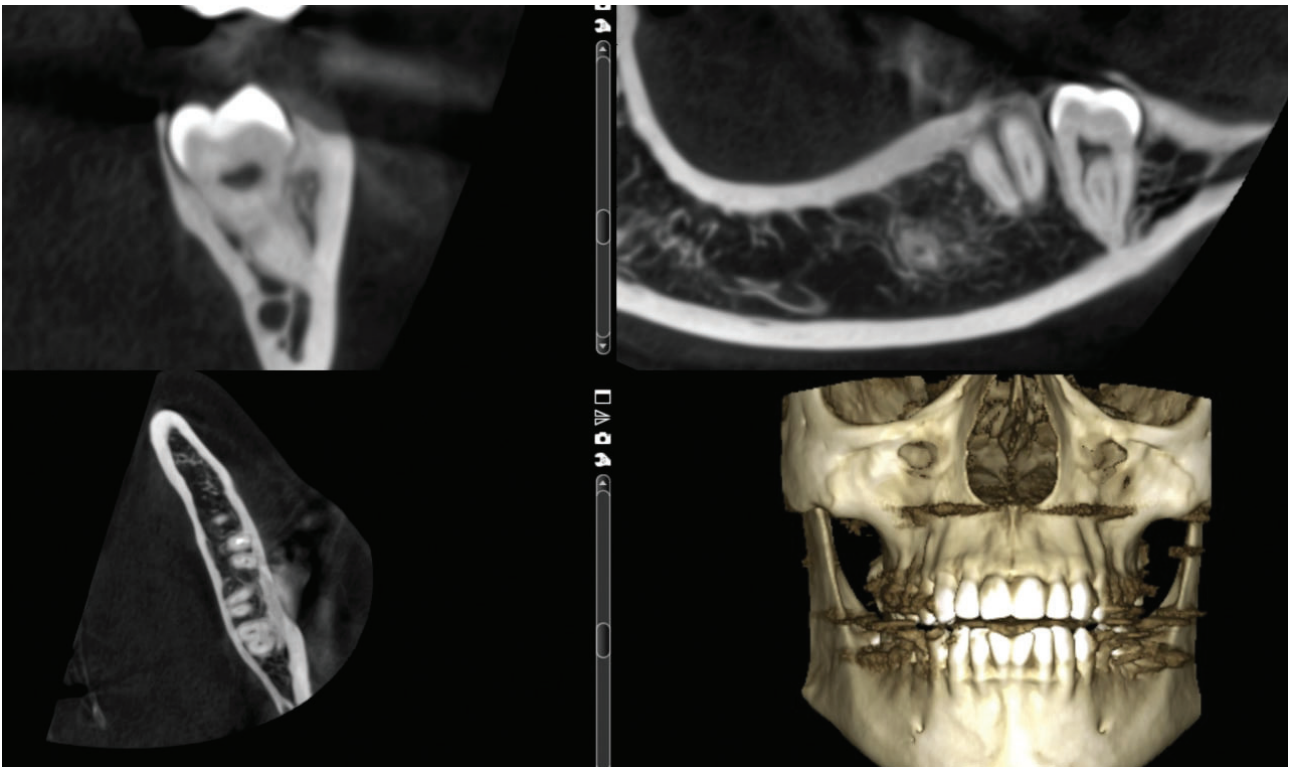
A bibliographic search was conducted in April 2022 by the using MESH terms equivalent to the keywords “tooth” and “autotransplantation” within the Cochrane Library and PubMed database with the aim to identify publications related with practical aspects of tooth autotransplantation presented in clinical case below. Additional search was provided via Google Search engine regarding available guidelines, clinical concepts, and standards of treatment by the same keywords. Inclusion and exclusion criteria were applied to identify literature outlining practically-oriented aspects regarding tooth autotransplantation operation, principles of tooth autotransplantation surgery and further post-endodontic restoration of autotransplanted tooth. Only exclusion criteria of selected studies were non-English language of publication. No quality analysis of the studies was provided, since the aim of literature search was to collect the data from publications directly or indirectly associated practically-oriented aspects regarding tooth autotransplantation presented in the following clinical case. Data extraction during content-analysis of selected publication were provided selectively in terms to represent the most practically valuable information regarding tooth autotransplantation operation, principles of tooth autotransplantation surgery and further post-endodontic restoration of autotransplanted tooth taking into account aspects highlighted in present clinical case.

#### Clinical Case Presentation

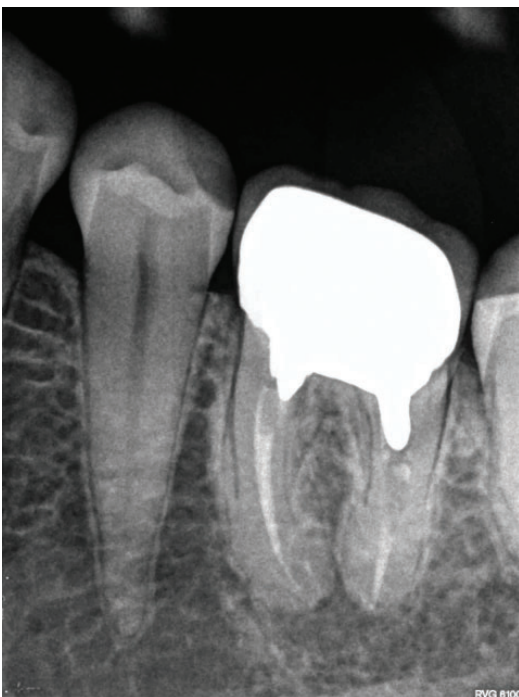
Young female patient presented to the endodontic clinic with a chief complaint of pain during biting at the projection of mandibular tooth on the left (Figure 1). Patient had results of previously provided CBCT examination (Figure 2). Clinical and radiographic examination revealed tooth #36, with previously treated root canals and fixed porcelain-fused-to-metal crown (Figure 3). CBCT scans revealed present periapical lesion. Periodontal probing revealed presence of periodontal pocket 5 mm in depth in one single site (Figure 4). Considering present pocket, specific J-shaped lesion, identified on obtained X-ray image and specific complaints, diagnose of the vertical root fracture (VRF) was established. Due to the fact that VRF is a non-treatable diagnosis, it was suggested to extract the tooth and place



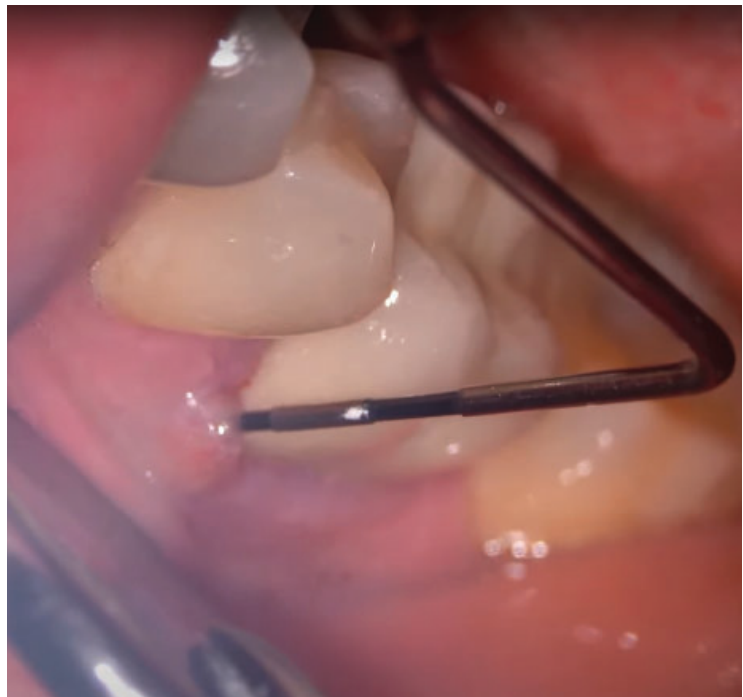**Figure 1.** Preoperative CBCT. Notice thick metal post in distal root canal of tooth #36, lesion around apices of roots.



**Figure 2.** Preoperative CBCT of impacted third molar: intact conditions, and mesiodistal dimensions are almost the same, as of tooth #36



**Figure 3.** Periapical X-ray of tooth #36



**Figure 4.** Periodontal probing depth demonstrated critical level at one site, which potentially is a sign of vertical root fracture

the implant instead. The patient was referred to an implantologist. Nevertheless, after careful collection of medical history and detailed analysis of CBCT scans, it was decided to autotransplant tooth #38 immediately after removal of tooth #36.

Careful comparative assessment of recipient site dimension and size of the donor tooth was provided based on available CBCT scans. After detailed comparison of the socket dimensions and sizes of

teeth #38 and #36 no need for additional manufacturing of tooth stereolithographic replica was established.

#### Transplantation procedure

Atraumatic extraction of tooth #36 was provided with periotomes, elevators and forceps under local anesthesia with 4% articaine hydrochloride plus 1:100 000 epinephrine. Extraction socket was



degranulated thoroughly with the aid of Lucas currettes, and after that it was abundantly rinsed with sterile saline to eliminate potential debris. Then, the wisdom tooth was atraumatically extracted in the same manner and examined for the absence of possible fractures. The total time during which the donor tooth was outside the oral cavity equaled to the less than 1 minute. Then it was placed in socket,

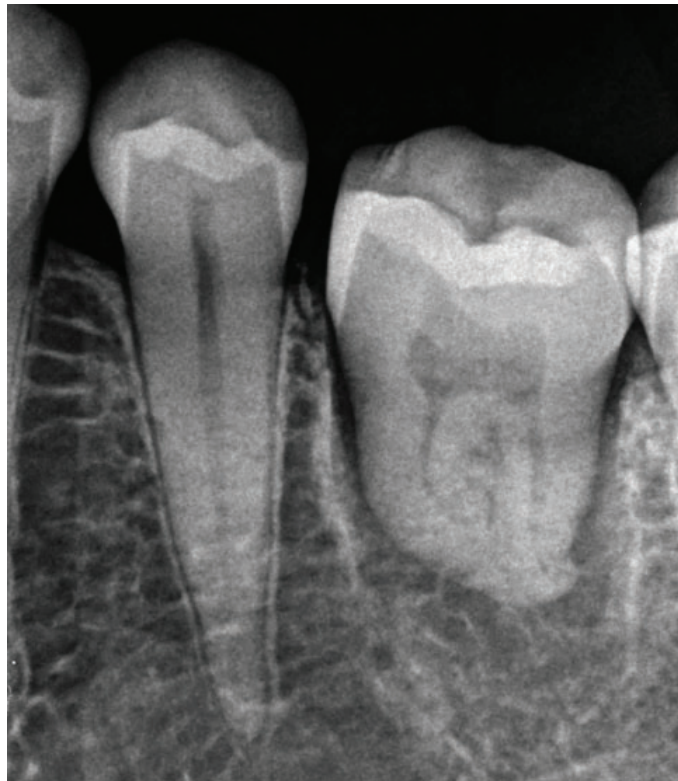

Figure 5. Periapical X-ray immediately after transplantation.

lower than occlusal level and splinted with bonded composite to neighboring teeth (Figure 5). Once again, occlusion was checked to ensure that there are no heavy contacts. There was no need for additional occlusal correction and tooth was stable in the socket.

Both sockets were sutured with PGLA Neosorb 6/0 absorbable sutures (Medipac, Greece). Non-steroidal anti-inflammatory drugs in the form of ibuprofen 200 mg 2 times/day for 3 days if necessary were prescribed to the patients. Patient was instructed to rinse with chlorhexidine biglucanate 0.12% (PerioAid, Dentaid, Greece) two times per day for the week.

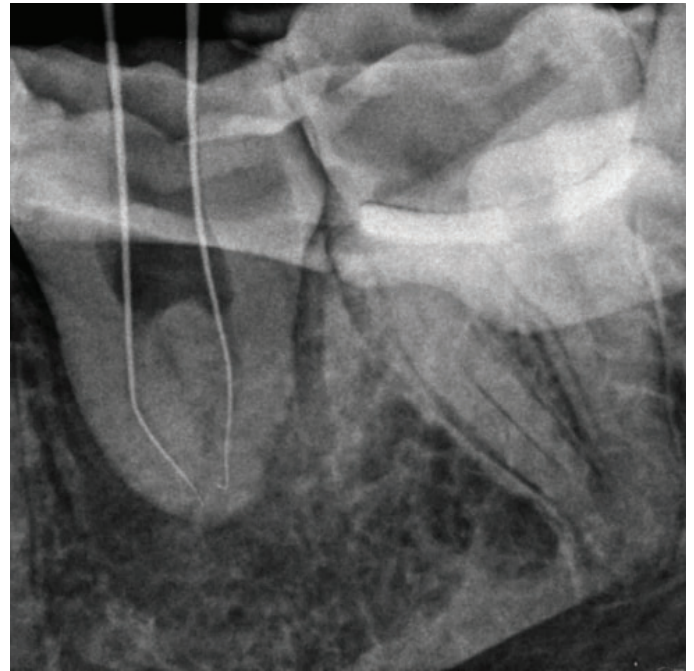


Figure 6. 14 days after transplantation root canal treatment was provided. Scouting procedure

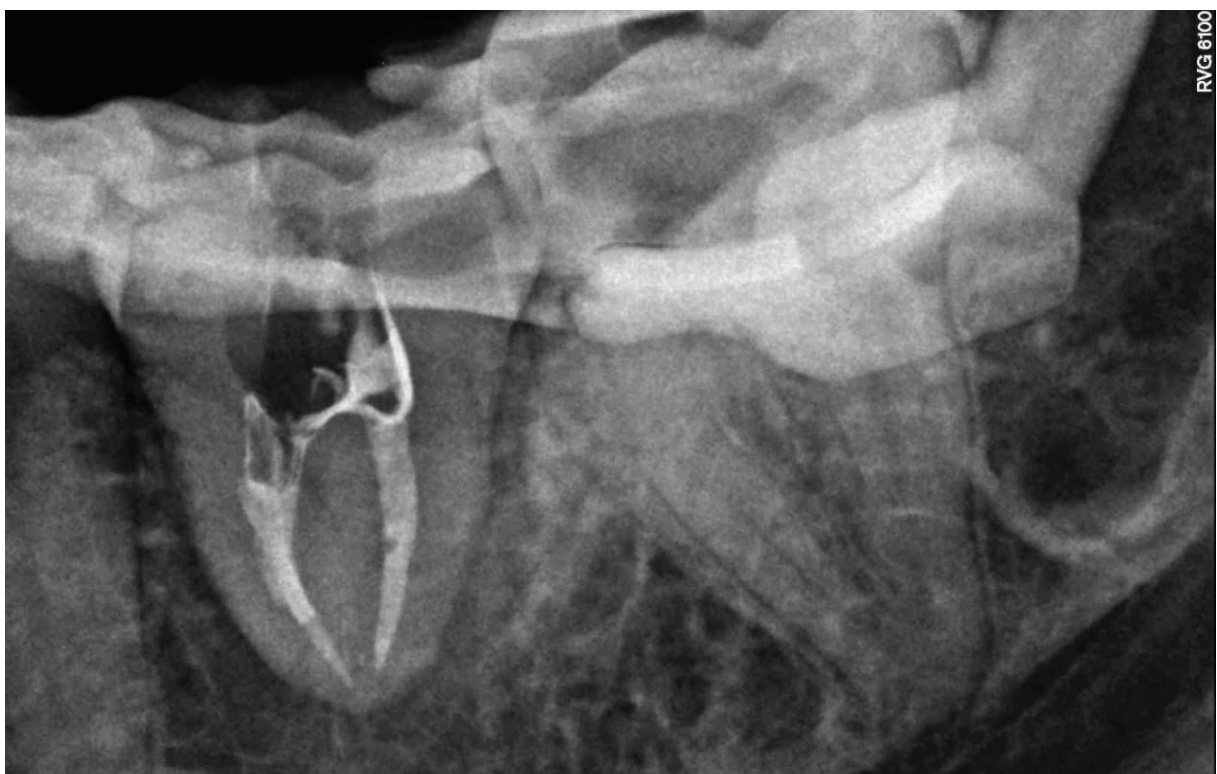

Figure 7. Periapical X-ray after root canal filling with warm gutta-percha.

### Endodontic treatment

Two weeks after the procedure the endodontic treatment was carried out. Root canals of autotransplanted tooth were instrumented, disinfected, and filled with gutta-percha points and AH-plus (Dentsply Sirona, USA) as a sealer (Figures 6-7). Same day the rest of the sutures were removed, as they were not needed anymore. Considering presence of ferrule, no functional need for cuspal coverage, structurally-promising prognosis, it was decided to restore the tooth with direct composite buildup as a long-term temporary restoration. Full contour pressed ceramic crown was chosen to be final restoration taking into account the ability to get 360 degrees peripheral intact enamel seal.

### Postoperative examinations and prosthetic restoration

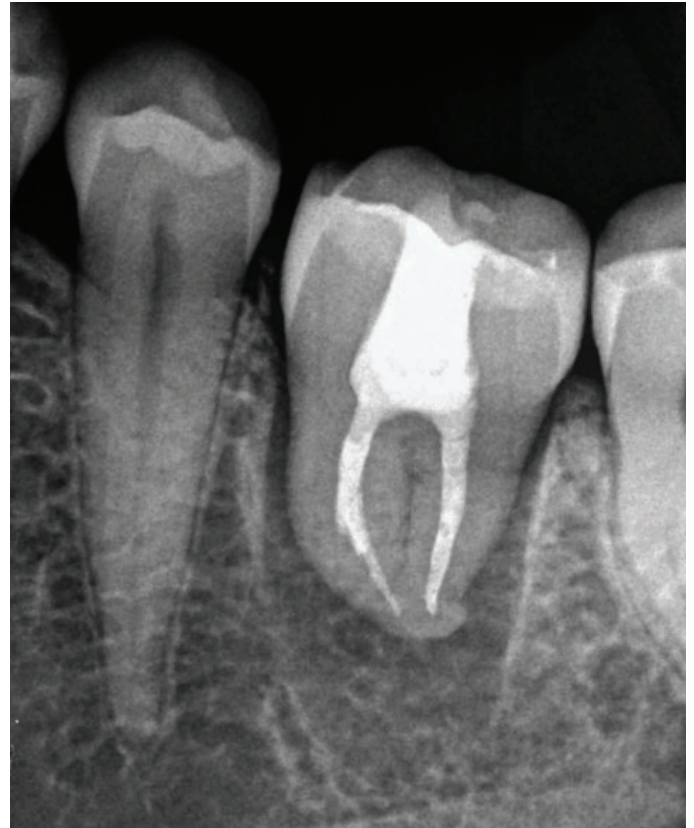At 1 month's recall the patient had no complaints and no soft tissue inflammation was evident. The splint was removed and tooth demonstrated no mobility (Figure 8).

6 months after the primary procedure patient came back to the dental office to continue the treatment. So far, clinically no signs of soft tissue inflammation were present, normal mobility (class I) was evident, and X-ray shown bone formation around transplanted tooth. No signs of neither periapical inflammation, nor periodontal were identified. Periodontal probing shown 2-3mm of depth in different sites around tooth. Tooth was completely asymptomatic.

At this stage given the lack of adequate occlusal contact with the antagonist teeth and the deficiency of correct contacts with neighboring teeth, it was decided to cover tooth with full contour ceramic crown as a final post endodontic restoration.

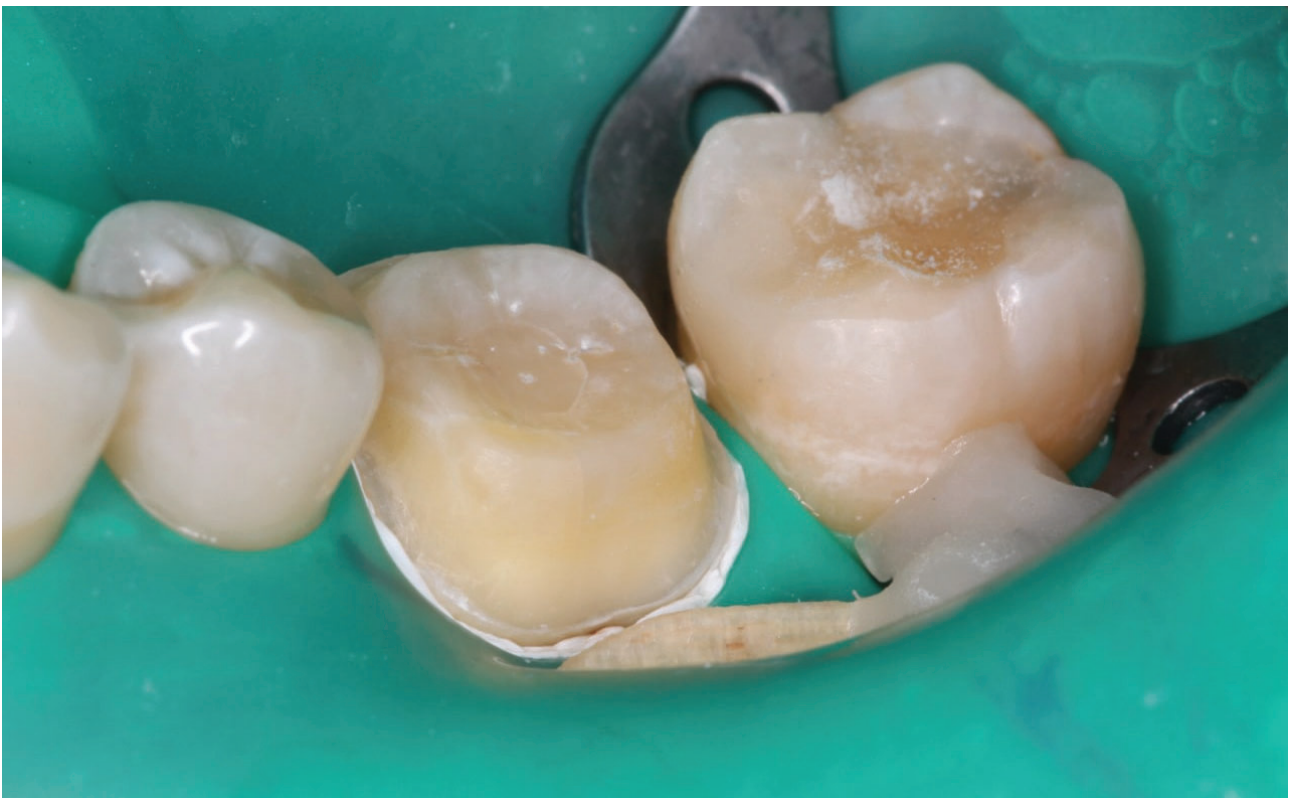Tooth 36 was prepared for a full crown, carefully saving peripheral enamel seals. Digital impressions were taken with a dental intraoral scanner (Figure 9). Single full contour crown was designed in CAD software, printed from a castable resin and pressed from IPS e.max (Ivoclar Vivadent, Schaan, Lichtenstein) ingot (Figure 10).

The final crowns were tried in intraorally. The occlusal contacts were checked in centric occlusion and lateral excursive movements using 8 µm articulation paper. Final adjustments regarding occlusion and approximal contacts were performed. The final crowns were cemented using transparent dual-cure self-adhesive resin cement



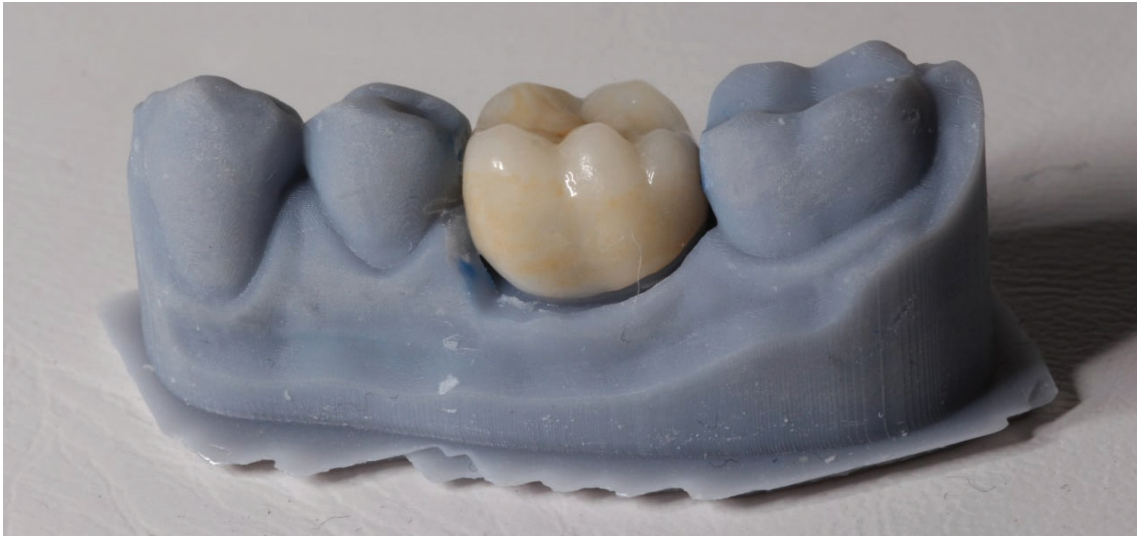**Figure 8.** X-ray 1 months after operation: no signs of inflammation

Variolink Esthetic DC (Ivoclar Vivadent, Schaan, Lichtenstein) according to manufacturer recommendations with Syntac three-step adhesive system (Figure 11). Postoperative instructions were given to the patient for care and maintenance, verbally and in writing form.

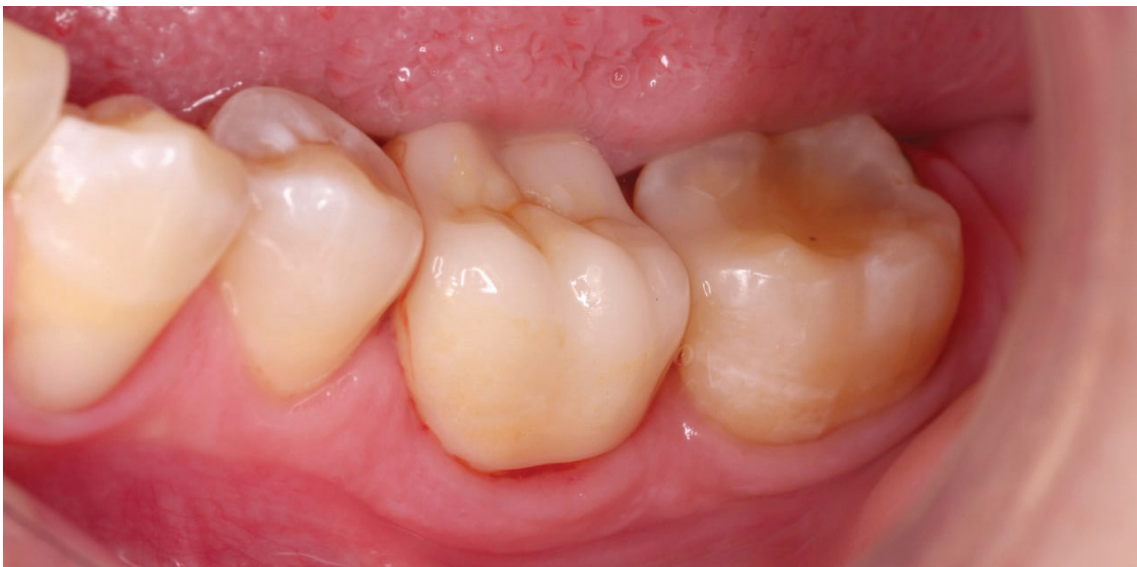

**Figure 9.** Transplanted tooth prepared for full-contour crown.

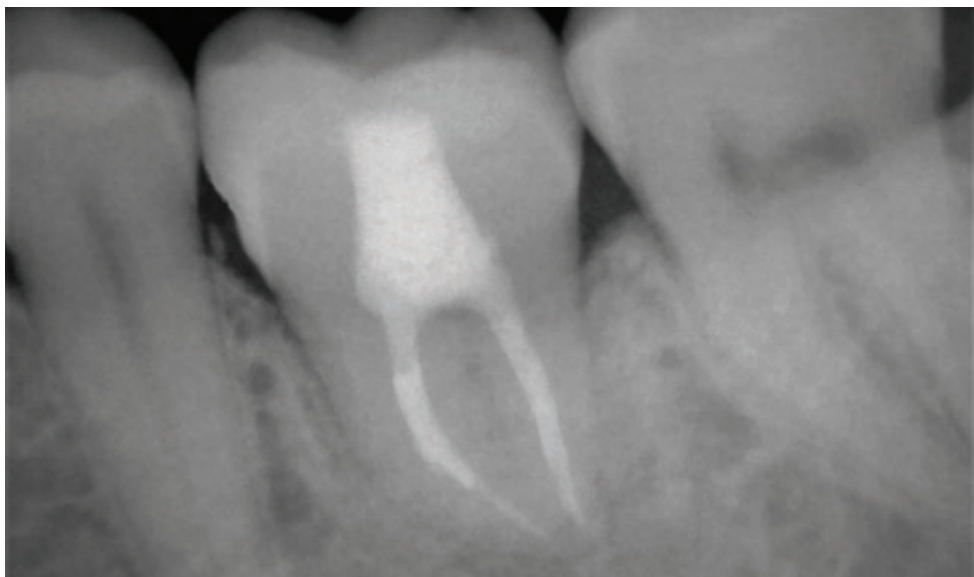




**Figure 10.** All-ceramic crown on printed model



**Figure 11.** Monolithic adhesive ceramic restoration right after cementation



**Figure 12.** Control periapical X-ray 2 months after permanent crown cementation

## Results

Patient was evaluated two months after crown cementation. No complaints, no signs of inflammation neither intraorally, nor on control periapical X-ray were identified (Figure 12).

## Discussion

Success rate of tooth autotransplantation is highly influenced by such factors as the stage of root development, morphology of the tooth, selected surgical procedure, time of extraoral exposure of donor tooth, shape of the recipient socket, vascularity of the recipient site, and the vitality of the periodontal ligament cells.

As described by Dioguardi et al. the outcome of the autotransplanted tooth can be defined as follows [5]:

- Success: no evidence of root resorption or ankylosis, inflammation, immobility, or periodontal pockets, and no pain in function;
- Survival: no pain, no inflammation but with root resorption or ankylosis;
- Failure or pathology: more than 3 mm of pocket from the end of the first year of transplantation, pain in function, abnormal mobility, infection at the recipient site [5].

Tooth autotransplantation requires meticulous selection of donor tooth and procedural planning to ensure success of clinical procedure.

### Prognostic factors and success

The autotransplantation procedure requires appropriate patient selection, that means motivated, cooperative patient with good oral hygiene, good general health without structural cardiac anomalies, and with a willingness and ability to attend regular recall appointments [7]. The recipient site should be free from acute infection and have enough bone support (the walls of the recipient socket must have acceptable dimensions to guarantee the stability of the donor tooth) with good bone quality to facilitate the transplanted tooth. The latter means that recipient socket should have an adequate thickness of the buccal and lingual cortical bone. The results of a clinical study conducted on 25 transplanted third molars suggested the use of drills under irrigation with normal saline solution during the preparation of the donor site [8]. To reduce the trauma, the bur must be round and operated at low speed [9]. Piezosurgery using tips with certain vibration frequencies can be used for the autotransplantation of non-erupted third molars to facilitate their removal from the bone, with few incisions on the periodontal fibers or the follicular sac, and to reduce the occurrence of ankylosis or root resorption.

Kafourou et al. described how the state of the periodontal ligament is key to the success of dental autotransplantation and that excessive trauma has a negative influence on the treatment outcome [10]. It of vital importance that the soft tissue surrounding the periodontal ligament, which represented also by cells of Hertwig's root sheath, should not be injured during the extraction. The same principle works with the apical papilla stem cells (SCAPs), which are fundamental for the root development of immature teeth [2]. An intact periodontal ligament around the tooth facilitates its growth and adaptation to the alveolar bone [11]. To avoid damage to intact periodontal ligament cells, the size of the new alveolus must be greater than that of the donor tooth; that also makes surgical procedure easier and a lot more predictable. This guarantees the preservation of the tissue and thus reduces the risk of ankylosis and external root resorption. Due to the Tsukiboshi et al. it is the most important factor for gaining clinical success [4]. Within about two weeks after the autotransplantation the reattachment between the connective tissues of the periodontal ligament of the donor tooth's root and the wall of the recipient alveolus takes place. The cells of periodontal ligament genetically can differentiate into osteoblasts, fibroblasts and cementoblasts [12–14]. In the ideal situation, it is hoped that the cells of the periodontal ligament facing the surface of the bone socket wall will differentiate into osteoblasts, stimulating the formation of bone, while the cells facing the external apical surface of the tooth will differentiate into cementoblasts, stimulating the deposition of dentin. The rate

of root surface recovery relies on how badly the root surface has been damaged. For tiny injured periodontal surfaces, healing can be accomplished through cementitious healing; however, when the amount of the damage is great, resorption of the root surface and replacement of dentin with bone occurs, which results in the loss of the tooth's root.

With regards to the donor tooth, relative contraindications include abnormal root morphology which would require surgical sectioning of the donor tooth. The biggest potential for retaining vitality and potential for further root development is shown by teeth with two-thirds complete root formation.

However, teeth with fully formed roots are not contraindicated and have shown good long-term results. In the case of an open apex, an immediate root canal treatment should not be performed, so that a follow-up can be carried out and the root may finish forming without showing signs or symptoms of infection. Root canal treatment is needed only when there are radiological signs of resorption or periapical pathology [15]. If the root canal treatment is necessary, it should be performed prior to transplantation or 15 days after. Teeth treated endodontically after autotransplantation procedure have a favorable prognosis. Because extraoral endodontic therapy can prolong the time between extraction and transplantation, it should be avoided. When undergoing extraoral endodontic therapy, there is also a chance that the periodontal ligament's cells and fibers could be harmed.

Another factor that had a significant impact on the treatment outcome is the surgical technique of tooth extraction. Ideally, the donor tooth has to be extracted as atraumatic as possible in order to avoid unnecessary damage to the root. Clinical observations had shown that third molars, extracted from young patients (15 to 19 years old) with immature roots, that have thicker follicle or periodontal ligament (PDL), better withstand damaging force during tooth extraction.

Extracted tooth has to be expose to extraoral environment for the shortest possible period of time to preserve the periodontal ligament and maintain Hertwig's epithelial sheath. In order to protect the periodontal ligament of the donor tooth, an intracrevicular incision could be performed before dislocating the tooth. The tooth is then kept safe within Hank's balanced salt solution. Hank's balanced salt solution is the most effective for sustaining the vitality of the periodontal ligament cells, followed by pasteurized milk, which is thought to be a viable option too. The temporary storage medium is a component that can affect the prognosis. The physiological compatibility of milk's pH, osmolality, and presence of nutrients and growth agents that could adhere to the root surface are some of its benefits.

Strbac et al. [19] suggested that during the storage tooth must be preserved within saline solution in order to not interfere the possibility of further pulp revascularization. Studies in the literature shown that the reduction of the surgical time, as well as period of extraoral tooth exposure could be achieved by using a replica of the transplanted tooth (most often 3D printed). On average, it helps to reduce the time of extraoral tooth exposure from 10 minutes to 1 minute [20]. Also, it has been shown that the less manipulation over the removed tooth is carried out, the more living cells of the periodontal ligament remain on the root surface, so such approach supports the likelihood of successful reintegration of the tooth into the alveolar socket.

Tooth stabilization, even though is not the most important factor, has a big impact on how the integration will occur: a lack of retention may be associated with trauma and instability while healing occurs [16]. Recommended period for retention is from 3 to 6 weeks, while tooth can be stabilized either with sutures, or with composite/wire splinting. It was originally thought that splinting could cause periodontal regeneration with fixation periods of up to 3 months and the use of rigid splints. However, it appeared that rigid splinting of the transplanted tooth can lead to disturbances in pulp revascularization [21]. According to some authors, the transplanted tooth's minor motions during function stimulate the growth of new blood vessels, while a hard splint's restricts tooth mobility and inhibits revascularization. This may be the cause of the frequent pulp necrosis occurrence among teeth retained with hard

splints. The occlusion should be checked to ensure that there is no occlusal interference; the occlusal adjustment should be more or less reduced. After some time, final restoration should be chosen to adjust the occlusion and/or the aesthetic appearance of the tooth.

Martin et al. has analyzed several systematic reviews regarding tooth autotransplantation, based on which it was reported that success and survival rate of teeth that underwent autotransplantation was more than 81% [17]. In 10-year perspective Rohof et al. reported success rate of near 90% among autotransplanted teeth with immature apex [18].

Negative prognostic factor for tooth autotransplantation outcome is the presence of cement tears, due to the onset of resorption phenomena in this regard [23]. Also, periodontal pocket depth of the donor tooth greater than 4 mm, age greater than 40 years, and previous endodontic treatment may cause inability of transplanted tooth to retain, according to Sugai et al. [22].

The lack of buccal cortex and a narrow recipient site, which could not provide sufficient support for donor tooth may be considered as negative prognostic factor. Pulp necrosis might result due to dimensions discrepancy between the recipient site and the root morphology of the transplanted tooth. Residues of inflamed tissue could damage the repair processes at bones and soft tissues after autotransplantation.

Due to the difficulty to prognose root development after transplantation and evaluate risk of root resorption, the success rate of autogenous tooth transplantation in the 1950s was only about 50%. The operation was rarely utilized due to the deficiency of understanding the factors associated with root resorption. Since 1990, a great deal of research has examined process of periodontal tissues repair, while also the frequency of root resorption following transplantation has been monitored. After that the success rate of transplanted teeth has increased quickly, causing upgrowing clinical interest. In 250 cases tracked for six years, Tsukiboshi et al. reported a 90% survival rate and an 82% success rate [4]. According to Lundberg and Isaksson, 94% of autotransplanted teeth with partially developed roots and 84% of those with fully formed roots were successful [24].

Successful autotransplantation requires careful patient selection and treatment planning, just like other surgical operations. Both the recipient site and the donor tooth should be carefully inspected for appropriateness and size correspondence. The recipient location should be free from infection and/or inflammation and have sufficient connected keratinized tissue and bone support to enable tooth stability.

It is preferable to preserve as much donor tooth structure as possible, since root canal treatment is compromising structural integrity of tooth after access preparation. Traditional crown requires occlusal reduction 1.5–2 mm, while also axial reduction of 1.2–1.5 mm, with shoulders heavily chamfered by 0.8–1 mm. During this kind of preparation, the majority of the tooth's hard structure is removed, leaving the tooth structurally weakened and with a residual dentine thickness of less than 1.5 mm. So, it is more preferable to minimize the volume of hard dental tissues reduction to assure sufficient amount of residual tooth structure.

## Conclusion

Present clinical case report with accompanied literature review arguments the clinical perspective of tooth autotransplantation procedure as valuable treatment option, and highlights major practically-oriented aspects regarding tooth autotransplantation operation including further post-endodontic restoration of donor tooth. Nevertheless, neither the autotransplantation protocol nor the post-endodontic restoration protocol by adhesive monolithic restorations are simple to realize correctly within clinical practice. But the synergy of these two techniques in the hands of an experienced doctor who is ready to carefully follow the scientific evidence-based protocol associated with successful outcome of provided treatment.

## Conflict of Interest

The author does not have any financial or property interests concerning the materials presented in this article.

## Funding

No funding was received to conduct this research.

## References

- Kassebaum NJ, Bernabé E, Dahiya M, Bhandari B, Murray CJ, Marcenes W. Global burden of severe tooth loss: a systematic review and meta-analysis. *J Dent Res.* 2014;93(7\_suppl):20S-8S. doi: 10.1177/0022034514537828
- Pecci Lloret MP, Martínez EP, Rodríguez Lozano FJ, Pecci Lloret MR, Guerrero Gironés J, Riccitiello F, Spagnuolo G. Influencing factors in autotransplantation of teeth with open apex: a review of the literature. *Appl Sci.* 2021;11(9):4037. doi: 10.3390/app11094037
- Ong D, Itskovich Y, Dance G. Autotransplantation: a viable treatment option for adolescent patients with significantly compromised teeth. *Aust Dent J.* 2016;61(4):396–407. doi: 10.1111/adj.12420.
- Tsukiboshi M. Autotransplantation of teeth: requirements for predictable success. *Dent Traumatol.* 2002;18(4):157–80. doi: 10.1034/j.1600-9657.2002.00118.x
- Dioguardi M, Quarta C, Sovereto D, Troiano G, Melillo M, Di Cosola M, Cazzolla AP, Laino L, Lo Muzio L. Autotransplantation of the third molar: a therapeutic alternative to the rehabilitation of a missing tooth: a scoping review. *Bioengineering.* 2021;8(9):120. doi: 10.3390/bioengineering8090120
- Boschini L, Melillo M, Berton F. Long term survival of mature autotransplanted teeth: A retrospective single center analysis. *J Dent.* 2020;98:103371. doi: 10.1016/j.jdent.2020.103371
- Armstrong L, O'Reilly C, Ahmed B. Autotransplantation of third molars: a literature review and preliminary protocols. *Br Dent J.* 2020;228(4):247–51. doi: 10.1038/s41415-020-1264-9
- Akiyama Y, Fukuda H, Hashimoto K. A clinical and radiographic study of 25 autotransplanted third molars. *J Oral Rehabil.* 1998;25(8):640–4. doi: 10.1046/j.1365-2842.1998.00215.x
- Teixeira CS, Pasternak Jr B, Vansan LP, Sousa-Neto MD. Autogenous transplantation of teeth with complete root formation: two case reports. *Int Endod J.* 2006;39(12):977–85. doi: 10.1111/j.1365-2591.2006.01170.x
- Kafourou V, Tong HJ, Day P, Houghton N, Spencer RJ, Duggal M. Outcomes and prognostic factors that influence the success of tooth autotransplantation in children and adolescents. *Dent Traumatol.* 2017;33(5):393–9. doi: 10.1111/edt.12353
- Giljames M, Baart JA, Wolff J, Sándor GK, Forouzanfar T. Tooth autotransplantation in the anterior maxilla and mandible: retrospective results in young patients. *Oral Surg Oral Med Oral Pathol Oral Radiol.* 2016;122(6):e187–92. doi: 10.1016/j.oooo.2016.06.013
- Trubiani O, Marconi GD, Pierdomenico SD, Piattelli A, Diomedede F, Pizzicannella J. Human oral stem cells, biomaterials and extracellular vesicles: a promising tool in bone tissue repair. *Int J Mol Sci.* 2019;20(20):4987. doi: 10.3390/ijms20204987
- Diomedede F, Marconi GD, Fonticoli L, Pizzicannella J, Merciaro I, Bramanti P, Mazzon E, Trubiani O. Functional relationship between osteogenesis and angiogenesis in tissue regeneration. *Int J Mol Sci.* 2020;21(9):3242. doi: 10.3390/ijms21093242
- Marconi GD, Fonticoli L, Guarnieri S, Cavalcanti MF, Franchi S, Gatta V, Trubiani O, Pizzicannella J, Diomedede F. Ascorbic acid: a new player of epigenetic regulation in LPS-gingivitis treated human periodontal ligament stem cells. *Oxid Med Cell Longev.* 2021;2021:6679708. doi: 10.1155/2021/6679708
- Abela S, Murtadha L, Bister D, Andiappan M, Kwok J. Survival probability of dental autotransplantation of 366 teeth over 34 years within a hospital setting in the United Kingdom. *Eur J Orthod.* 2019;41(5):551–6. doi: 10.1093/ejo/cjz012



16. Anitua E, Mendinueva-Urkia M, Galan-Bringas S, Murias-Freijo A, Alkhraisat MH. Tooth autotransplantation as a pillar for 3D regeneration of the alveolar process after severe traumatic injury: a case report. *Dent Traumatol.* 2017;33(5):414-9. doi: 10.1111/edt.12354
17. Martin K, Nathwani S, Bunyan R. Autotransplantation of teeth: an evidence-based approach. *Br Dent J.* 2018;224(11):861-4. doi: 10.1038/sj.bdj.2018.432
18. Rohof E, Kerdijk W, Jansma J, Livas C, Ren Y. Autotransplantation of teeth with incomplete root formation: a systematic review and meta-analysis. *Clin Oral Investig.* 2018;22(4):1613-24. doi: 10.1007/s00784-018-2408-z
19. Strbac GD, Giannis K, Mittlböck M, Fuerst G, Zechner W, Stavropoulos A, Ulm C. Survival rate of autotransplanted teeth after 5 years—a retrospective cohort study. *J Craniomaxillofac Surg.* 2017;45(8):1143-9. doi: 10.1016/j.jcms.2017.03.023
20. EzEldeen M, Wyatt J, Al-Rimawi A, Coucke W, Shaheen E, Lambrechts I, Willems G, Politis C, Jacobs R. Use of CBCT guidance for tooth autotransplantation in children. *J Dent Res.* 2019;98(4):406-13. doi: 10.1177/0022034519828701
21. Kristerson L, Andreassen JO. The effect of splinting upon periodontal and pulpal healing after autotransplantation of mature and immature permanent incisors in monkeys. *Int J Oral Surg.* 1983;12(4):239-49. doi: 10.1016/s0300-9785(83)80049-0
22. Sugai T, Yoshizawa M, Kobayashi T, Ono K, Takagi R, Kitamura N, Okiji T, Saito C. Clinical study on prognostic factors for autotransplantation of teeth with complete root formation. *Int J Oral Maxillofac Surg.* 2010;39(12):1193-203. doi: 10.1016/j.ijom.2010.06.018
23. Jang Y, Choi YJ, Lee SJ, Roh BD, Park SH, Kim E. Prognostic factors for clinical outcomes in autotransplantation of teeth with complete root formation: survival analysis for up to 12 years. *J Endod.* 2016;42(2):198-205. doi: 10.1016/j.joen.2015.10.021
24. Lundberg T, Isaksson S. A clinical follow-up study of 278 autotransplanted teeth. *Br J Oral Maxillofac Surg.* 1996 Apr 1;34(2):181-5. doi: 10.1016/s0266-4356(96)90374-5

## Клінічні аспекти аутотрансплантації зуба та постендодонтичного відновлення аутотрансплантованого зуба: огляд літератури на основі клінічних випадків

Ігор Ноєнко<sup>A, C, E, F</sup>

лікар-стоматолог, Інститут Стоматології, Національний університет охорони здоров'я України імені П. Л. Шупика, Київ, Україна ORCID ID: 0000-0002-0644-2702

Костянтин Костура<sup>C, D</sup>

лікар-стоматолог, приватна практика, Київ, Україна  
ORCID ID: 0000-0003-3348-5713

Олександр Ходаков<sup>B</sup>

лікар-стоматолог, приватна практика, Київ, Україна  
ORCID ID: 0000-0002-5288-4763

Відповідальний автор для листування: Ігор Ноєнко, Інститут Стоматології, Національний університет охорони здоров'я України імені П. Л. Шупика, Новопольова, 36, оф. 1, м. Київ, 03061 Україна  
E-mail: nickmess1@gmail.com

A – розробка концепції та дизайну дослідження, B – збір та або систематизація даних дослідження, C – аналіз та тлумачення даних дослідження, D – написання публікації, E – критичне доопрацювання тексту публікації, F – остаточне затвердження.

### Стаття:

Історія статті:

Надійшла до редакції 15 червня 2022  
Прийнята до друку 4 липня 2022  
Доступна онлайн 1 Жовтня 2022

Ключові слова:

реплантація зубів,  
трансплантація, ендодонтія,  
реставрація зубів, огляд

### Анотація

**Вступ.** Аутотрансплантація зуба дозволяє зберегти життєдіяльність періодонтальної зв'язки, що в свою чергу сприяє збереженню об'єму альвеолярної кістки, кращій підтримці стану міжзубного сосочка та зберігає можливість ортодонтичного переміщення зуба, при потребі. Є данні, що терміни виживання та прогноз аутотрансплантованих зубів можна порівняти з дентальними імплантатами.

**Мета.** Обговорити основні практичні аспекти операції аутотрансплантації зубів, включаючи подальшу постендодонтичну реставрацію на основі представленого клінічного випадку.

**Матеріали та методи.** У квітні 2022 року було проведено бібліографічний пошук із використанням термінів MESH, еквівалентних ключовим словам «зуб» і «аутотрансплантація» в у базі даних Cochrane Library та PubMed з метою виявлення публікацій, які пов'язані з практичними аспектами аутотрансплантації зубів, представлених в клінічних випадках. Під час контент-аналізу вибір даних з обраних публікацій здійснювався вибірково з точки зору представлення найбільш практично цінної інформації щодо операції аутотрансплантації зуба, принципів хірургії аутотрансплантації зуба та подальшого постендодонтичного відновлення аутотрансплантованого зуба, з урахуванням аспектів, висвітлених у цьому клінічному випадку.

**Результати.** На підставі представленого огляду літератури було зазначено, що на успіх аутотрансплантації зуба великий вплив мають такі чинники, як стадія розвитку кореня, морфологія зуба, обрана хірургічна процедура, час позаротової експозиції донорського зуба, форма реципієнтної лунки, васкуляризація реципієнтної ділянки та життєздатність клітин періодонтальної зв'язки, вплив яких враховувався у представленому клінічному випадку.

**Висновки.** Представлений звіт про клінічний випадок, із супровідним оглядом літератури, аргументує клінічну перспективу процедури аутотрансплантації зуба як цінного біологічного варіанту лікування та висвітлює основні клінічні аспекти операції аутотрансплантації зуба, включаючи подальше постендодонтичне відновлення донорського зуба. Синергія протоколів аутотрансплантації зуба та постендодонтичної реставрації в руках команди лікарів, які готові ретельно дотримуватися науково-доказового протоколу призводить до довгострокового успіху лікування.

### Конфлікт інтересів

Автор не має жодних фінансових чи майнових інтересів щодо матеріалів, представлених у цій статті.

### Фінансування

Не було отримано жодного фінансування на проведення цього дослідження.